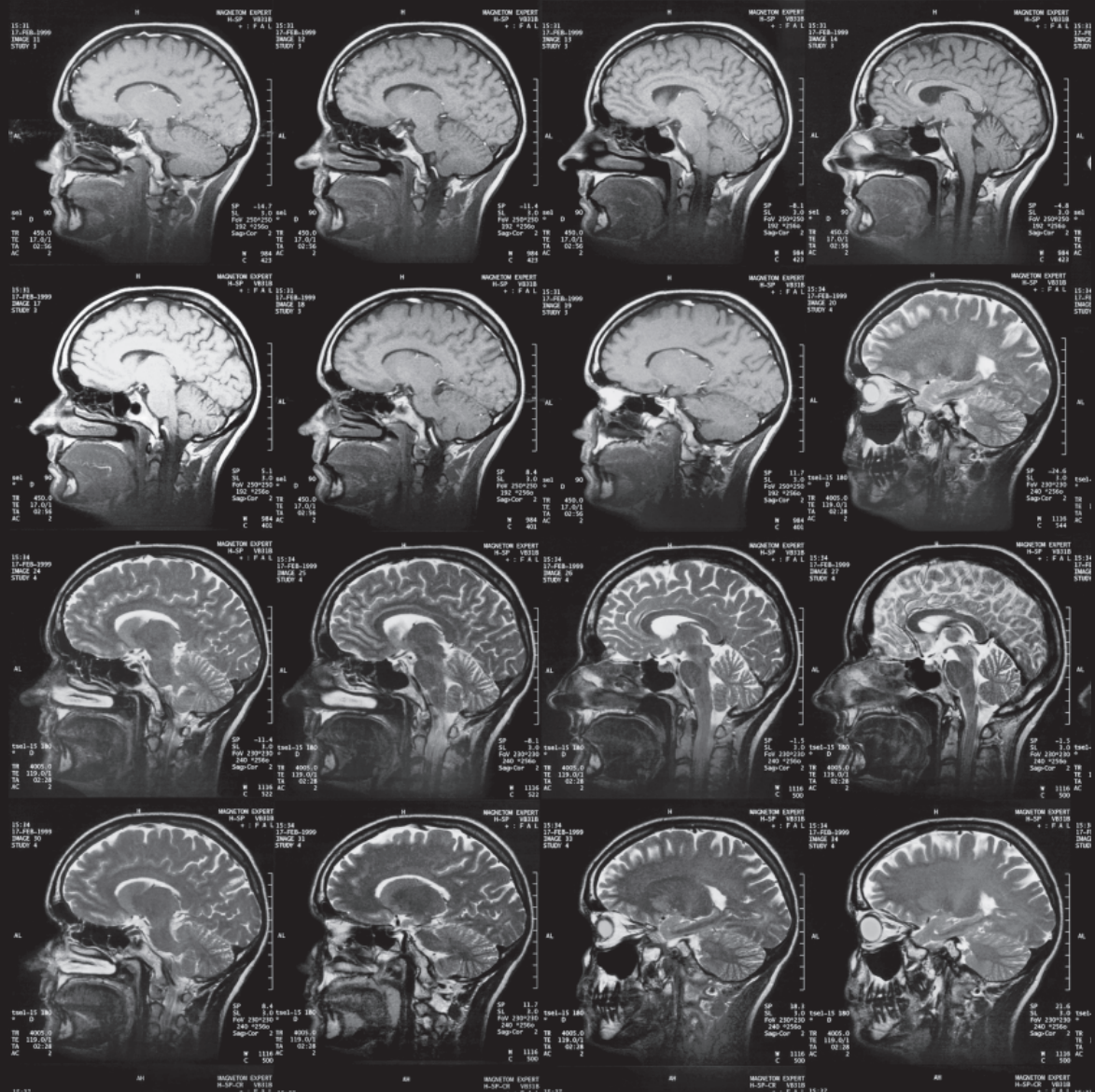


**GLENCOE**



**Cover Photo:** Simon Fraser/Photo Researchers, Inc.

**Photo and Illustration Credits:**

Dr. Sterling Clarren, 29

**Photo Researchers, Inc.:** Airelle-Joubert, 34; AJPhoto, 14; Anatomical Travelogue, 9; John Bavosi, 5, 10, 37; Tim Beddow, 19; Biophoto Associates, 8; Scott Camazine, 1, 4, 15, 40, 41; Gary Carlson, 7; Charing Cross Hospital, 20; Michael Donne, 15; S. Faser, 43; Simon Fraser, 11, 35, 36; Dr. Robert Friedland, 47; GJLP, 45; Pascal Goetgheluck, 26, 27, 28, 30; Mehau Kulyk, 31, 32, 33; Dr. J. Mazziotta et al./Neurology, 22; MediVisuals (*Amygdala and Hippocampus added by Publisher*), 2; Alfred Pasioka, 24; Phanie, 16, 17, 20, 46; Dr. M. Phelps & Dr. J. Mazziotta et al./Neurology, 21; Will & Deni McIntyre, 19; Hank Morgan, 25, 39; Hans-Ulrich Osterwalder, 48; Erich Schrempp, 18; Dr. Neal Scolding, 6; Science Source, 12, 13, 28; WDCN/ Univ. College London, 23; Zephyr, 3, 42, 44

**Brand Name Disclaimer**

Publisher does not necessarily recommend or endorse any particular company or brand name product that may be discussed or pictured in *The Developing Brain e-Transparencies*. Brand name products are used because they are readily available, likely to be known to the reader, and their use may aid in the understanding of the text. Publisher recognizes other brand name or generic products may be substituted and work as well or better than those featured in *The Developing Brain e-Transparencies*.



**Glencoe**

*The McGraw-Hill Companies*

Copyright © by The McGraw-Hill Companies, Inc. All rights reserved. Permission is granted to reproduce the material contained herein on the condition that such materials be reproduced only for classroom use; be provided to students, teachers, and families without charge; and be used solely in conjunction with *The Developing Child* program. Any other reproduction, for sale or other use, is expressly prohibited.

Send all inquiries to:  
Glencoe/McGraw-Hill  
21600 Oxnard Street, Suite 500  
Woodland Hills, CA 91367

1 2 3 4 5 6 7 8 13 12 11 10 09

# The Developing Brain e-Transparencies



- 1 Lobes of the Human Brain
- 2 Brain Anatomy
- 3 Scan of the Brain from the Front
- 4 Coronal Section of the Brain
- 5 Limbic System of the Brain
- 6 Brain Cells in the Grey Matter
- 7 Neurons Are Nerve Cells
- 8 Nerve Cells of the Cerebral Cortex
- 9 Synapses Make Connections
- 10 Synaptic Junction Between Neurons
- 11 The Developing Brain In Utero
- 12 Brain Development (Birth to 6 months)
- 13 Brain Development (20 months to 5 years)
- 14 Electroencephalogram (EEG)
- 15 Computed Tomography (CT) Scan
- 16 CT Scan of Healthy Brain (Axial Section)
- 17 Magnetic Resonance Imaging (MRI) Scan
- 18 MRI Head Scan Showing Slicing Nature of MRI Imaging
- 19 Positron Emission Tomography (PET) Scan
- 20 Single-Photon Emission Computed Tomography (SPECT) Scan
- 21 Positron Computed Tomography (PCT) Scans of Visual Stimulation
- 22 Positron Computed Tomography (PCT) Scans of Auditory Stimulation
- 23 Activity Areas in the Brain
- 24 Pineal Gland

*Continued*

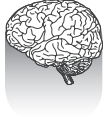- 25** PET Scans During Sleep
- 26** PET Scans Showing MAO B (red) and Dopamine Levels (blue)
- 27** PET Scans of the Effects of THC on Cerebellum Activity
- 28** PET Scans of a Cocaine User's Brain
- 29** Fetal Brain Damage Caused by Alcohol
- 30** PET Scans of the Effects of Alcohol Withdrawal
- 31** MRI Scan of Brain with Holoprosencephaly
- 32** MRI Scan of Brain with Sturge-Weber Syndrome
- 33** MRI Scan of Brain with Multiple Sclerosis
- 34** CT Scan of Brain with Encephalitis
- 35** MRI Scan of Brain with Meningitis
- 36** MRI Scan of Brain with Creutzfeldt-Jakob Disease
- 37** Illustration of an Epileptic Seizure's Impact on the Brain
- 38** PET Scans Showing the Stages of an Epileptic Seizure
- 39** PET Scan of Brain with Schizophrenia (Off Medication)
- 40** CT Scan of Brain Hemorrhage
- 41** CT Scan of Glioma (Tumor) and Removal
- 42** MRI Scan of Brain Cancer
- 43** MRI Scan of Cerebral Atrophy
- 44** Magnetic Resonance Angiography (MRA) Showing a Stroke
- 45** CT Scan of Brain with Parkinson's Disease
- 46** CT Scans Showing the Effect of Alzheimer's on the Brain
- 47** PET Scans Showing the Effect of Alzheimer's on the Brain
- 48** The Progression of Alzheimer's Disease

# Teaching Suggestions for The Developing Brain e-Transparencies

## Lobes of the Human Brain

Transparency 1

This illustration of the brain identifies the **frontal lobe**, **parietal lobe**, **occipital lobe**, and **temporal lobe**. The cerebellum is labeled as a reference point for location within the cerebral hemisphere.

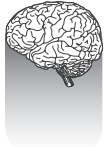

**Brain Research Activity**—Have students research the function of each lobe within the human brain. Ask students to create a *Brain Lobe Chart* identifying the function of each lobe of the brain.

## Brain Anatomy

Transparency 2

This illustration identifies basic brain anatomy. The **forebrain** is made up of the **cerebrum**, **thalamus**, **hypothalamus**, **amygdala**, and **hippocampus**. Note the location of the **midbrain**. The **hindbrain** is composed of the **cerebellum**, **pons**, and **medulla oblongata**.

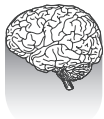

**Brain Research Activity**—Have students research the function of the cerebrum, thalamus, hypothalamus, amygdala, hippocampus, cerebellum, pons, and medulla oblongata. Ask students to create a *Brain Anatomy Chart* showing how each part forms part of the forebrain, midbrain, or hindbrain.

## Scan of the Brain from the Front

Transparency 3

Colored composite 3-D magnetic resonance imaging (MRI) scan of a human brain, seen from the front. The **ventricles** (purple) circulate the cerebrospinal fluid, which cushions the brain. One lateral ventricle lies in each (left and right) cerebral hemisphere. Beneath the lateral ventricles are the sensory-processing **thalami** (yellow) and the **hypothalamus** (green, center), which controls emotion and body temperature and releases chemicals that regulate the hormones released from the **pituitary gland** (green, lower).

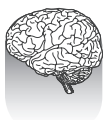

**Brain Research Activity**—Have students research the function of the brain's four ventricles, the two thalami, the hypothalamus, and the pituitary gland. Ask students to create a *Frontal Scan Chart* explaining how each part works together within the brain.

## Coronal Section of the Brain

Transparency 4

This illustration shows a **coronal section** of the human brain. A coronal section is easy to visualize because it is like looking directly through a person who is facing you. Notice the fairly symmetrical left and right hemispheres. The **anterior view**, or front section of the brain, is closest to the face, nose, and mouth. The **posterior view**, or rear section of the brain, is closest to the back of the head.



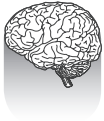**Brain Research Activity**—Ask students to research coronal sections of the human brain to determine the parts they can identify on Transparency 4. Have volunteers label the parts using water-based markers. Discuss whether this transparency shows an anterior or a posterior view.



## Limbic System of the Brain

Transparency 5

This is a colored illustration of the limbic system in the human brain. The **limbic system** is a complex network of nerve pathways that govern the expression of fear, rage, and pleasure and is involved in the formation of memory. Key areas of the limbic system include the **hypothalamus**, **hippocampus**, and **amygdala**. Parts of the thalamus are considered by some to also be in the limbic system. The cerebellum and corpus callosum are labeled as a reference point.

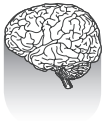

**Brain Research Activity**—Have students research the limbic system and the function of each part within it. Ask students to create a *Limbic System Chart* explaining the function of each part.

## Brain Cells in the Grey Matter

Transparency 6

This fluorescence light micrograph shows assorted brain cells in the **grey matter**. A nerve cell is seen in bright green with branched dendrites extending outward.



**Brain Research Activity**—Have students research the differences between grey matter and white matter in the human brain. Ask them to share their *Grey Matter Versus White Matter* findings with the class and create a composite list of what they learned.

## Neurons Are Nerve Cells

Transparency 7

**Neurons** are nerve cells that transmit, receive, and process information. This illustration shows neurons within connecting distance of one another.

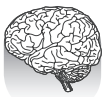

**Brain Research Activity**—Ask students to research neurons. Have students draw a neuron and label all the parts, including the axon and the dendrites. Post their drawings in the classroom.

## Nerve Cells of the Cerebral Cortex

Transparency 8

This medical image shows nerve cells of the human **cerebral cortex**.

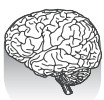

**Brain Research Activity**—Have students research the cerebral cortex and find out how densely populated the cerebral cortex is with neurons (nerve cells). Discuss their findings.

## Synapses Make Connections

Transparency 9

Synapses are the junctions across which nerve impulses travel. Neurons fire bursts of electrical messages along filaments. Axons are the longest of these filaments (some reach up to 3 ft.). Axons carry messages away from the cell body at speeds over 200 mph. Knob-like feet at the end of each axon contain neurotransmitters that further speed the process along.

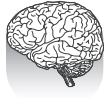

**Brain Research Activity**—Ask students to research synapses and their role in transmitting signals from the brain to and from the body. Have students write a *Synapse Connection* report.

## Synaptic Junction Between Neurons

Transparency 10

This vivid illustration focuses on the **synaptic junction** (knob) between two neurons (nerve cells). When an electrical impulse reaches the synapse, vesicles (round blue shapes) burst through the cell membrane and release neurotransmitters (red spheres) that cross the synaptic cleft (or gap) between the two cells. When the neurotransmitters reach the receptor cell, they bind to the cell and trigger an electrical impulse in the receptor cell. The cigar-shaped (green) mitochondria are the sites of energy production taking place within the cell.

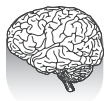

**Brain Research Activity**—Have students continue their research on synapses. Ask them to form teams and role-play the synaptic junction between neurons.

## The Developing Brain In Utero

Transparency 11

This magnetic resonance imaging (MRI) scan shows a fetus (pink) during the 36<sup>th</sup> week of pregnancy. Note the **developing brain** near the base of the image.

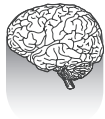

**Brain Research Activity**—Have students research the rate at which the brain develops during pregnancy. Ask volunteers to share their findings with the class.

## Brain Development (Birth to 6 months)

Transparency 12

These magnetic resonance imaging (MRI) scans show a newborn's brain and the brain of a 6-month-old. Note the differences between the two brains.



**Brain Research Activity**—Have students research how the brain develops from birth through six months of age. Ask students to share their findings in groups of three and then report back to the entire class.

## Brain Development (20 months to 5 years)

Transparency 13

These magnetic resonance imaging (MRI) scans show a 20-month-old brain and the brain of a 5-year-old. Note the differences between the two brains.



**Brain Research Activity**—Have students research how the brain develops through 5 years of age. Ask students to share their findings in groups of three and then report back to the entire class.

## Electroencephalogram (EEG)

Transparency 14

This 4-year-old girl is undergoing an **electroencephalogram (EEG)** to monitor the electrical activity of her brain. A normal EEG is shown on the computer screen.



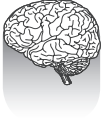**Brain Research Activity**—Have students research the electroencephalogram (EEG) process and identify normal results and what abnormal results will tell a physician. Ask volunteers to read their reports to the class.

## Computed Tomography (CT) Scan

Transparency 15

(A) This female patient is being administered a **computed tomography (CT) scan**. In CT scanning short bursts of low dose X-rays are passed through the body at different angles. A computer then produces a cross-sectional image of the tissues. CT scans provide more detail than normal X-rays, yet reduce the patient's exposure to radiation. CT scans produce good contrast between tissues and bone and are useful in diagnosing tumors and blood clots.

(B) This colored CT scan of a healthy brain shows the cerebral hemispheres in orange and the ventricles in black. The irregular blue shape at upper center is the pineal gland.

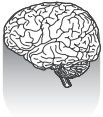

**Brain Research Activity**—Have students research computed tomography and determine what an abnormal CT could tell a physician. Ask volunteers to share their findings and abnormal CT scans with the entire class.

## CT Scan of Healthy Brain (Axial Section)

Transparency 16

This CT scan of a healthy brain is shown in **axial (horizontal) section**. The skull (white) circles the two hemispheres of the brain (grey) divided by the longitudinal cerebrum. The ventricular cavities are filled with cerebrospinal fluid (dark grey).

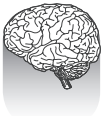

**Brain Research Activity**—Have students research the various ways a brain can be sectioned: axial, coronal, and sagittal. Ask students to work in groups to create a visual presentation of how these sections can be used in CT scans.

## Magnetic Resonance Imaging (MRI) Scan

Transparency 17

A **magnetic resonance imaging (MRI) scan** provides an unparalleled view inside the human body. MRI is the method of choice to diagnose many types of injuries and conditions because of the incredible ability to tailor the exam to the particular medical question being asked. By changing exam parameters, the MRI system can cause tissues in the body to take on different appearances. MRI systems can also image flowing blood in virtually any part of the body.

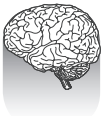

**Brain Research Activity**—Have students research the magnetic resonance imaging process and determine what an abnormal MRI could tell a physician. Ask volunteers to share their findings and abnormal MRI scans with the entire class.

## MRI Head Scan Showing Slicing Nature of MRI Imaging

Transparency 18

Eight sections of an MRI head scan of a healthy 16-year-old male. The images are seen in perspective to show the **slicing nature of MRI imaging**.



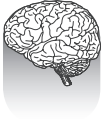**Brain Research Activity**—Have students research how the slicing nature of MRI scans can help physicians focus on specific injuries or conditions. Ask volunteers to share their findings with the entire class.



## Positron Emission Tomography (PET) Scan

Transparency 19

**Positron Emission Tomography (PET) scans** are used to study the level of function in tissues as opposed to the structural information given by CT scans. PET scanning relies on a radioactive tracer, injected into the bloodstream, to reveal metabolic activity in the brain. In this color-coded PET scan, the cerebral layer shows brain activity from low (blue) to high (yellow). Notice how normal brain metabolic activity produces a roughly symmetrical pattern in the yellow areas of the left and right cerebral hemispheres. In many brain dysfunctions (such as Alzheimer's disease, epilepsy, and schizophrenia), PET scans are useful in pinpointing specific areas which are metabolically affected by disease.

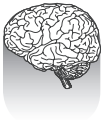

**Brain Research Activity**—Have students research the positron emission tomography and determine what an abnormal PET scan could tell a physician. Ask volunteers to share their findings and abnormal PET scans with the entire class.

## Single-Photon Emission Computed Tomography (SPECT) Scan

Transparency 20

This colored **Single-Photon Emission Computed Tomography (SPECT) scan** of a healthy brain in axial (horizontal) section shows areas of high activity (red, yellow) and low activity (grey, blue). In SPECT scanning a radioactive tracer is injected into the bloodstream to reveal metabolic activity in the brain. SPECT scans can also show areas of the brain that are affected by disease or brain dysfunction.

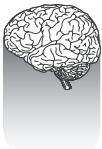

**Brain Research Activity**—Have students research single-photon emission computed tomography and determine what an abnormal SPECT could tell a physician. Ask volunteers to share their findings and abnormal SPECT scans with the entire class.

## Positron Computed Tomography (PCT) Scans of Visual Stimulation

Transparency 21

**Positron computed tomography (PCT) scans** of the brain are taken after the patient has been injected with a very small dose of a radioactive chemical that binds to glucose. The resulting scan shows glucose concentration in parts of the brain where there is increased activity (cerebral metabolism). Then a computer maps how the brain responds to different stimuli. This transparency shows how the brain's activity level changes in response to three forms of **visual stimulation** (i.e., eyes closed; eyes open; complex scene).

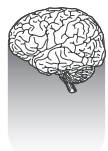

**Brain Research Activity**—Have students research positron computed tomography and the various ways physicians use this type of brain scan to address various diseases and conditions that affect vision. Ask students to share their findings in groups of three and then report back to the entire class.

## Positron Computed Tomography (PCT) Scans of Auditory Stimulation

Transparency 22

Positron computed tomography (PCT) scans of the brain are taken after the patient has been injected with a very small dose of a radioactive chemical that binds to glucose. The resulting scan shows glucose concentration in parts of the brain where there is increased activity (cerebral metabolism). Then a computer maps how the brain responds to different stimuli. This transparency shows how the brain's activity level changes in response to four forms of **auditory stimulation** (i.e., resting state; language and music; language only; music only).

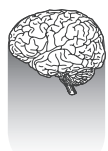

**Brain Research Activity**—Have students research positron computed tomography and the various ways physicians use this type of brain scan to address various diseases and conditions that affect hearing. Ask students to share their findings in groups of three and then report back to the entire class.

## Activity Areas in the Brain

Transparency 23

These colored PET scans show areas of high metabolic activity in the brain when it is activated by different tasks. Sight activates the visual area in the **occipital cortex**. Hearing activates the auditory area in the **temporal cortex**. Touching Braille script activates the **tactile parietal area** and an area of cognition. Thoughts in the **frontal cortex** are used to generate words.

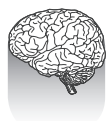

**Brain Research Activity**—Have students research the functions of the occipital cortex, temporal cortex, tactile parietal area, and the frontal cortex within the human brain. Divide the students into four groups and assign each group one brain activity area. Ask each group to make a presentation to the class about their assigned *Brain Activity Area*.

## Pineal Gland

Transparency 24

This computer artwork of a sectioned human brain in side view shows the pineal gland. The **pineal gland** is located just below the back of the corpus callosum. It secretes the hormone melatonin, which controls the body's biological clock. Melatonin is mainly secreted at night, which helps induce sleep.

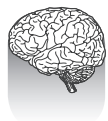

**Brain Research Activity**—Have students research the pineal gland and the function of melatonin. Ask students to discuss the implication of too little melatonin and whether or not melatonin can be regulated by other means when traveling across multiple time zones.

## PET Scans During Sleep

Transparency 25

These PET scans show brain activity in a person who gets normal sleep and brain activity in a person who suffers from sleep deprivation.



**Brain Research Activity**—Have students research the stages of sleep and the health implications of sleep deprivation. Ask them to discuss the impact of sleep deprivation on brain function during waking hours.

## PET Scans Showing MAO B (red) and Dopamine Levels (blue)

Transparency 26

These colored PET scans compare levels of **monoamine oxidase B (MAO B)** found in the brain of a smoker (bottom) and a non-smoker (top). MAO B is an enzyme which breaks down **dopamine**, a neurotransmitter chemical involved in motivation and behavior. MAO B levels are highest in the red areas and lower in the following color sequence: yellow to green to blue (lowest). The smoker's brain has much lower levels of MAO B, which leads to higher levels of dopamine being present. Dopamine is involved in reinforcing behavior.

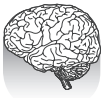

**Brain Research Activity**—Have students research the role of monoamine oxidase (MAO B) and dopamine in the human brain. Ask students to discuss how smoking affects the brain.

## PET Scans of the Effects of THC on Cerebellum Activity

Transparency 27

These colored PET scans compare the differing levels of activity in the brains of a non-marijuana user (top) and marijuana user (bottom). Marijuana contains the psychoactive drug **tetrahydrocannabinol (THC)**. THC reduces brain activity in the cerebellum (lower parts of the four scans on the right) and causes a lack of coordination and poor spatial judgment. Red areas of high activity can be seen in the non-user's cerebellum. Red areas are absent in the marijuana user. *Note:* Scans show progressively deeper slices of the brain from left to right.

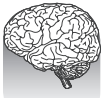

**Brain Research Activity**—Have students research the effects of THC on the human brain. Ask volunteers to report their findings to the entire class.

## PET Scans of a Cocaine User's Brain

Transparency 28

These colored PET scans show the effect of cocaine use on the human brain. A cocaine user's brain is less active than a healthy brain. The red and yellow areas indicate high activity. Blue and purple indicate low activity. *Note:* Scans show progressively deeper slices of the brain from left to right.

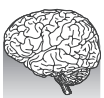

**Brain Research Activity**—Have students research the effects of cocaine on the human brain. Ask them to also research the impact of cocaine use on fetal development. Discuss their findings as a class.

## Fetal Brain Damage Caused by Alcohol

Transparency 29

This transparency compares a healthy brain with a fetal alcohol brain. Fetal alcohol syndrome is not curable. However, early intervention can greatly improve the child's life. Alcohol damage to the fetus varies due to the volume of alcohol ingested at which stage of pregnancy as well as genetics and other factors.

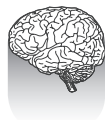

**Brain Research Activity**—Have students research the impact fetal alcohol syndrome has on brain development. Ask students to find out how the brain can set up alternative pathways to the damaged areas of the brain if intervention occurs early enough in life.

## PET Scans of the Effects of Alcohol Withdrawal

Transparency 30

These colored PET scans show an alcoholic's brain during withdrawal. The top two images show brain activity levels after 10 days of withdrawal and the bottom two images show brain activity after 30 days. The red and yellow areas indicate high activity in the brain. Blue and purple areas indicate lower levels of brain activity. Notice how the activity levels increase as withdrawal time increases. *Note:* Scans show progressively deeper slices of the brain from left to right.

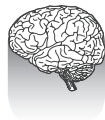

**Brain Research Activity**—Have students research the effects of alcohol withdrawal on brain activity. Ask students to share their findings in groups of three and then report back to the entire class.

## MRI Scan of Brain with Holoprosencephaly

Transparency 31

This transparency shows a colored MRI scan of a brain with **holoprosencephaly**. In this congenital condition, a large abnormal ventricle (pink and blue fluid-filled cavity) forms where the forebrain would normally be. Two healthy ventricles (blue and pink) are shown on the lower left and right. People with holoprosencephaly often have no olfactory system (smell), as well as defects in the optic nerve and pituitary gland.

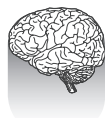

**Brain Research Activity**—Have students research the effects of holoprosencephaly, its causes, frequency of occurrence, and treatment options. Ask students to share their findings in groups of three and then report back to the entire class.

## MRI Scan of Brain with Sturge-Weber Syndrome

Transparency 32

This colored MRI scan shows a brain with **Sturge-Weber syndrome**. People with this congenital disorder are mentally handicapped and may suffer from epileptic seizures. The brain is shown in horizontal (axial) section. The fluid-filled ventricles (upper center and lower right) are green. Notice that part of the brain has calcified (blue).

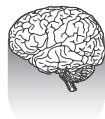

**Brain Research Activity**—Have students research the effects of Sturge-Weber syndrome, its causes, frequency of occurrence, and treatment options. Ask students to discuss their findings with the entire class.

## MRI Scan of Brain with Multiple Sclerosis

Transparency 33

This colored MRI scan shows the brain of a 10-year-old girl suffering from **multiple sclerosis (MS)**. MS is believed to be an autoimmune disorder in which the immune system destroys the myelin sheaths around the axon nerve fibers of the brain and spinal cord. Axons in the affected area can no longer conduct nerve impulses. Notice the large demyelinated lesion in the lower left (green). In this horizontal (axial) section the brain's fluid-filled ventricles (upper center) are also shown in green.

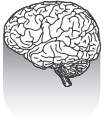

**Brain Research Activity**—Have students research multiple sclerosis and the role that myelin plays in the human brain. Ask students to share their findings in groups of three and then report back to the entire class.

## CT Scan of Brain with Encephalitis

Transparency 34

This CT scan of an adult's brain shows **encephalitis** in the right temporal caused by an infection with the herpes virus (encephalitis herpetica). Encephalitis results in the inflammation of the **encephalon** (red area) and causes personality disorders and amnesia.

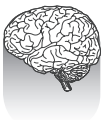

**Brain Research Activity**—Have students research the effects of encephalitis on the human brain and the function of the encephalon. Ask students to read articles about the frequency of encephalitis. Discuss their findings as a class.

## MRI Scan of Brain with Meningitis

Transparency 35

This colored MRI scan shows a sagittal section through the head of a 34-year-old woman with meningitis. The meningitis infection is colored yellow on the brain and spinal cord. Meningitis is an inflammation of the meninges, the membranes that cover and protect the brain and spinal cord. It is caused by either bacterial or viral infection.

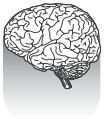

**Brain Research Activity**—Have students research the effects of meningitis on the human brain and the bacterial and viral infections that can cause it. Ask students to share their findings in groups of three and then present a report to the entire class.

## MRI Scan of Brain with Creutzfeldt-Jakob Disease

Transparency 36

This colored MRI scan shows the brain of a 17-year-old male with **Creutzfeldt-Jakob disease** (CJD). The thalami (two yellow areas) are diseased. CJD destroys nerve cells and causes brain tissue to become spongy. CJD is detected as a “bilateral signal abnormality” on a MRI.

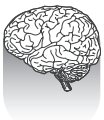

**Brain Research Activity**—Have students research the effects of Creutzfeldt-Jakob disease on the human brain. Ask students to explore the potential link between CJD and “mad cow’s disease.” Discuss their findings as a class.

## Illustration of an Epileptic Seizure's Impact on the Brain

Transparency 37

This abstract artwork was created based on a patient's description of what an **epileptic seizure** feels like. The large shaft of lightning runs along the end of a nerve cell and across the synapse to another cell. The pink spheres crossing the synaptic junction are neurotransmitters (chemical messengers) that carry an impulse from one nerve cell to the next. Epileptic seizures are caused by chaotic electrical activity in the brain. Attacks can be triggered by a variety of factors.



**Brain Research Activity**—Have students research the effects of epilepsy, its potential causes, frequency of occurrence, and treatment options. Ask students to share their findings in groups of three and then report back to the entire class.



## PET Scans Showing the Stages of an Epileptic Seizure

Transparency 38

These three PET scans show the brain during the various stages of an epileptic seizure.

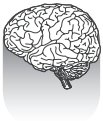

**Brain Research Activity**—Have students research the effects of epileptic seizures on the human brain. Ask students to create an illustration of each stage of an epileptic seizure in the brain, referring to Transparency 37 for ideas. Discuss how their illustrations reflect their findings.

## PET Scan of Brain with Schizophrenia (Off Medication)

Transparency 39

This PET scan shows the brain with **schizophrenia** as it looks off all medication. Notice there is very little activity in the frontal lobe. Red and yellow indicate high levels of brain activity. Green and blue indicate lower levels of brain activity.

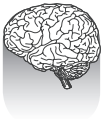

**Brain Research Activity**—Have students research the effects of schizophrenia on the human brain and the ages at which the disease presents versus when it is often diagnosed. Ask students to share their findings in groups of three and then report back to the entire class.

## CT Scan of Brain Hemorrhage

Transparency 40

This color-enhanced CT scan shows a **hemorrhage** of the left posterior temporal lobe of the brain. Hemorrhages can be caused by a variety of factors.

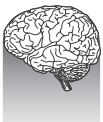

**Brain Research Activity**—Have students research the potential causes of a hemorrhage, the frequency of occurrence, implications of the location of the hemorrhage, and treatment options. Discuss their findings as a class.

## CT Scan of Glioma (Tumor) and Removal

Transparency 41

These colored CT scans show a brain **glioma** in a 16-year-old girl before surgery (left image) and the brain after the tumor has been removed (right image). A new type of MRI called **diffusion tensor imaging** is providing surgeons with a better view inside and limiting the destruction of nerves, blood vessels, and tissue caused by surgeries such as this one.

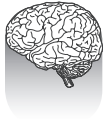

**Brain Research Activity**—Have students research the potential causes of a glioma, the frequency of occurrence, implications of the location of the glioma, and treatment options. Ask students to also research diffusion tensor imaging and share their DTI scans with the entire class. Discuss their findings about gliomas and how DTI will impact future surgeries.

## MRI Scan of Brain Cancer

Transparency 42

This colored MRI scan of an axial section through a patient's brain shows a tumor (black area, upper left) that has spread (metastasized) from a **malignant melanoma**, a form of skin cancer. Malignant melanomas invade and destroy surrounding tissues and often spread. The risk of developing melanoma is increased by excessive exposure to sunlight.

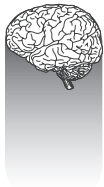

**Brain Research Activity**—Have students research the potential causes of malignant melanomas and the effects they can have on the human brain. Ask students to discuss their findings with the entire class.

## MRI Scan of Cerebral Atrophy

Transparency 43

This colored MRI scan shows a sagittal section through the brain of a 51-year-old male with **cerebral atrophy**. Atrophy is shrinkage and wasting away of tissue. Atrophy of parts of the cerebrum can occur in various disorders, including stroke, Alzheimer's disease, and AIDS dementia. The area of the upper cerebrum affected by atrophy is colored dark red.

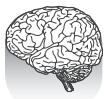

**Brain Research Activity**—Have students research the potential causes of cerebral atrophy and the effects it can have on the human brain. Divide the students into three groups and assign each group one of the following: stroke, Alzheimer's disease, or AIDS dementia. Ask each group to make a presentation to the class about their assigned disorder that can cause cerebral atrophy.

## Magnetic Resonance Angiography (MRA) Showing a Stroke

Transparency 44

This colored three-dimensional MRA (magnetic resonance angiography) scan shows internal bleeding (red, center right) in a stroke victim's brain. The brain damage caused by a **stroke** results from the pressure of the internal bleeding. In this case the bleeding is in the left hemisphere of the brain, causing paralysis in the right half of the body as well as aphasia (a speech disorder).



**Brain Research Activity**—Have students research the potential effects of a stroke on the human brain. Ask students to share their findings with the entire class.

## CT Scan of Brain with Parkinson's Disease

Transparency 45

This colored CT scan shows an axial (horizontal) slice through the brain of a patient with **Parkinson's disease**. The fluid-filled ventricles are blue. Parkinson's disease has caused the lower ventricles to increase in size as the brain loses density due to the death of cerebral tissue. Parkinson's disease is caused by deterioration in clusters of brain cells called the basal ganglia, which help to control muscle movement.

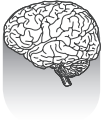

**Brain Research Activity**—Have students research the effects of Parkinson's disease on the human brain. Discuss their findings as a class.

## CT Scans Showing the Effect of Alzheimer's on the Brain

Transparency 46

These colored CT scans compare an axial (horizontal) section of a healthy brain on the left with a brain affected by **Alzheimer's disease** on the right. Alzheimer's disease causes the destruction (dark blue edges) and shrinkage of the brain (cortical atrophy) away from the skull.

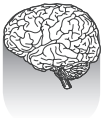

**Brain Research Activity**—Have students research the effects of Alzheimer's disease on the brain. Ask students to share their findings in groups of three and then report back to the entire class.

## PET Scans Showing the Effect of Alzheimer's on the Brain

Transparency 47

These colored PET scans compare an axial (horizontal) section of a healthy brain (left) with the brain of an Alzheimer's patient (right). Red and yellow areas indicate high levels of brain activity. Blue and black indicate low brain activity. The Alzheimer's scan shows a reduction of function on both sides of the brain.

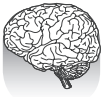

**Brain Research Activity**—Have students research how PET scans are used to help determine the treatment options for Alzheimer's patients. Ask volunteers to share their findings with the entire class.

## The Progression of Alzheimer's Disease

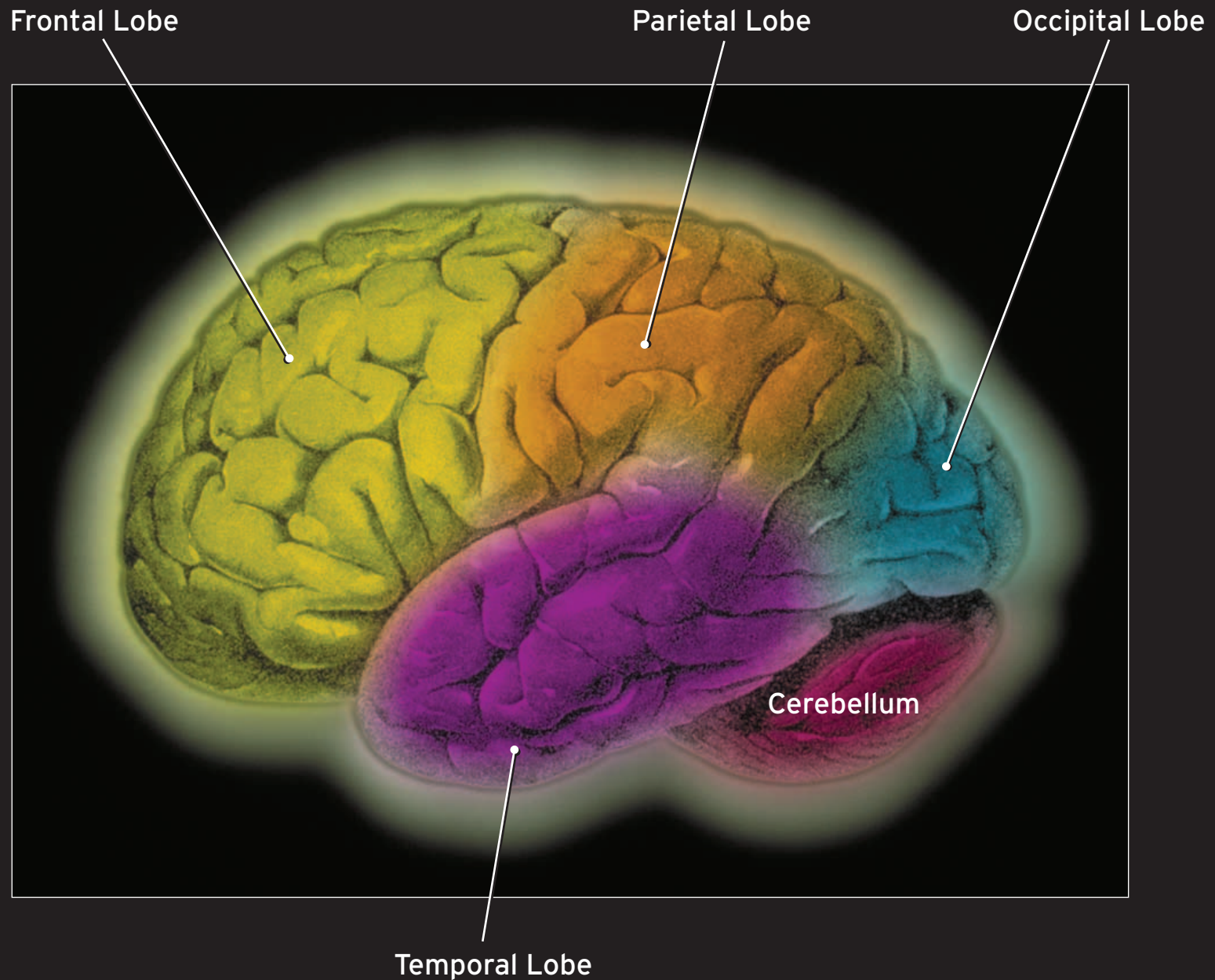
Transparency 48

This conceptual computer artwork illustrates the death of brain cells as commonly found in Alzheimer's disease. The causes of Alzheimer's are associated with the formation of plaques of insoluble protein in the brain, and decreased levels of acetylcholine (a neurotransmitter).

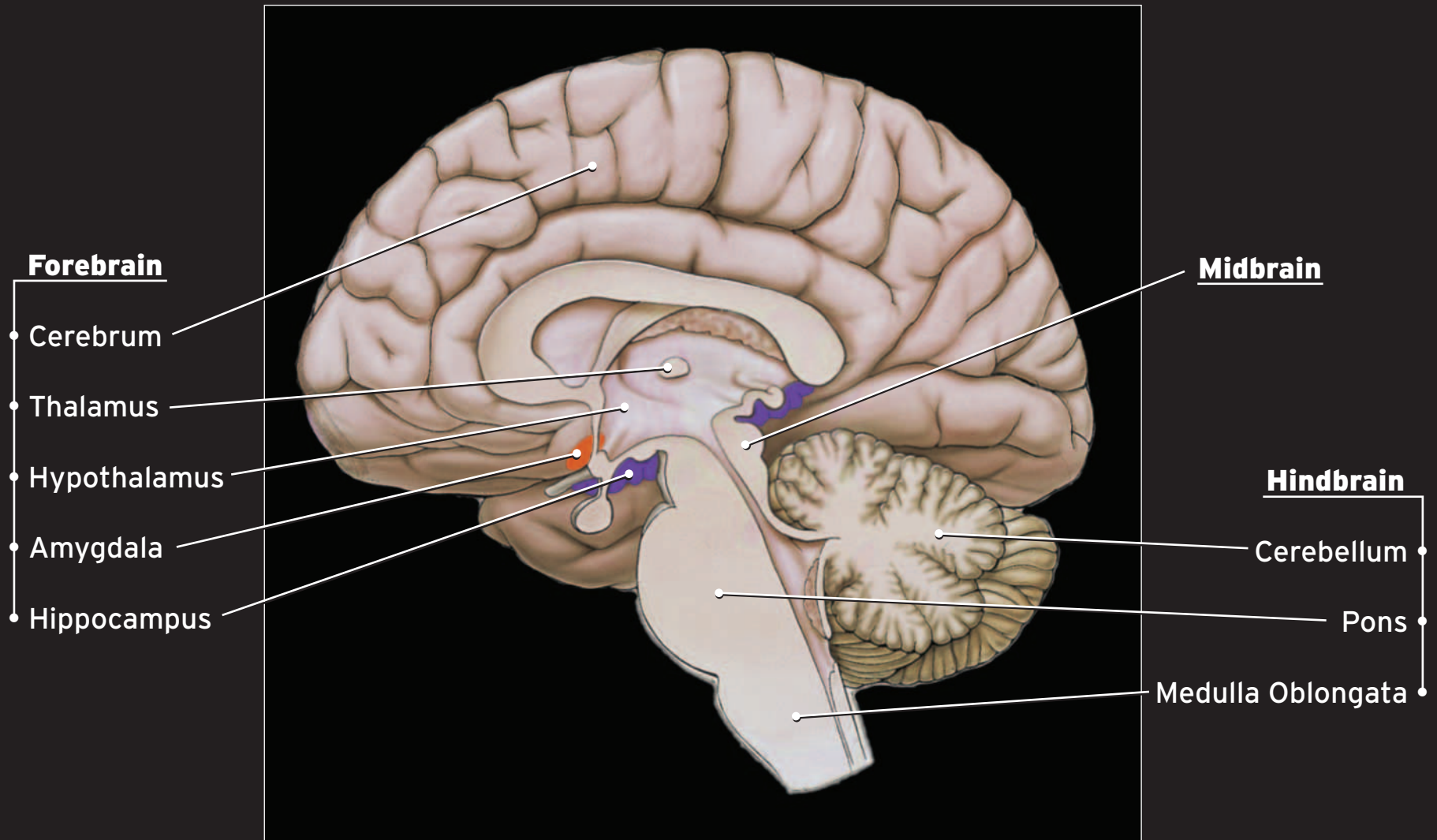


**Brain Research Activity**—Have students research the death of brain cells and how that relates to Alzheimer's disease. Discuss their findings as a class.

# Lobes of the Human Brain

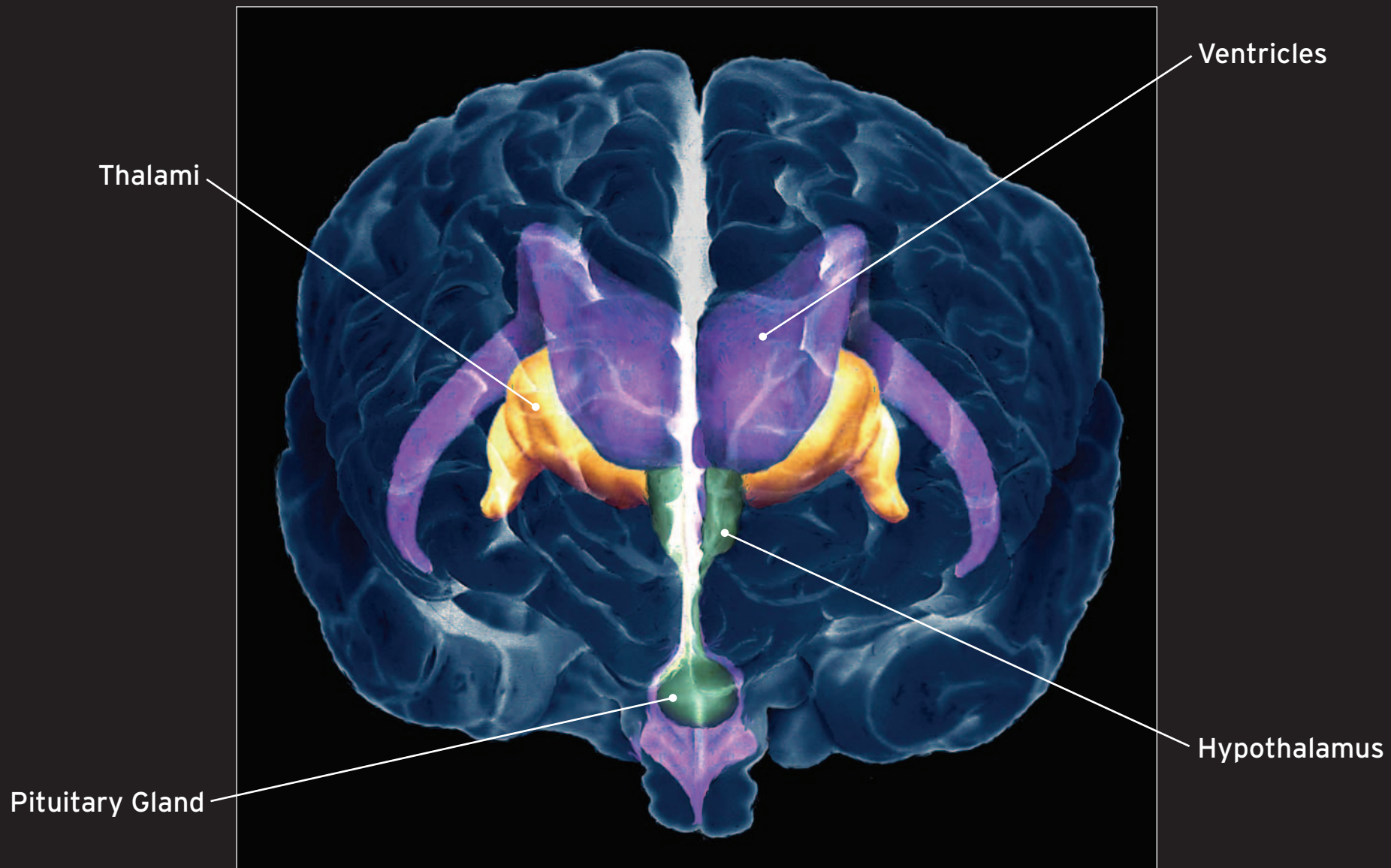


# Brain Anatomy

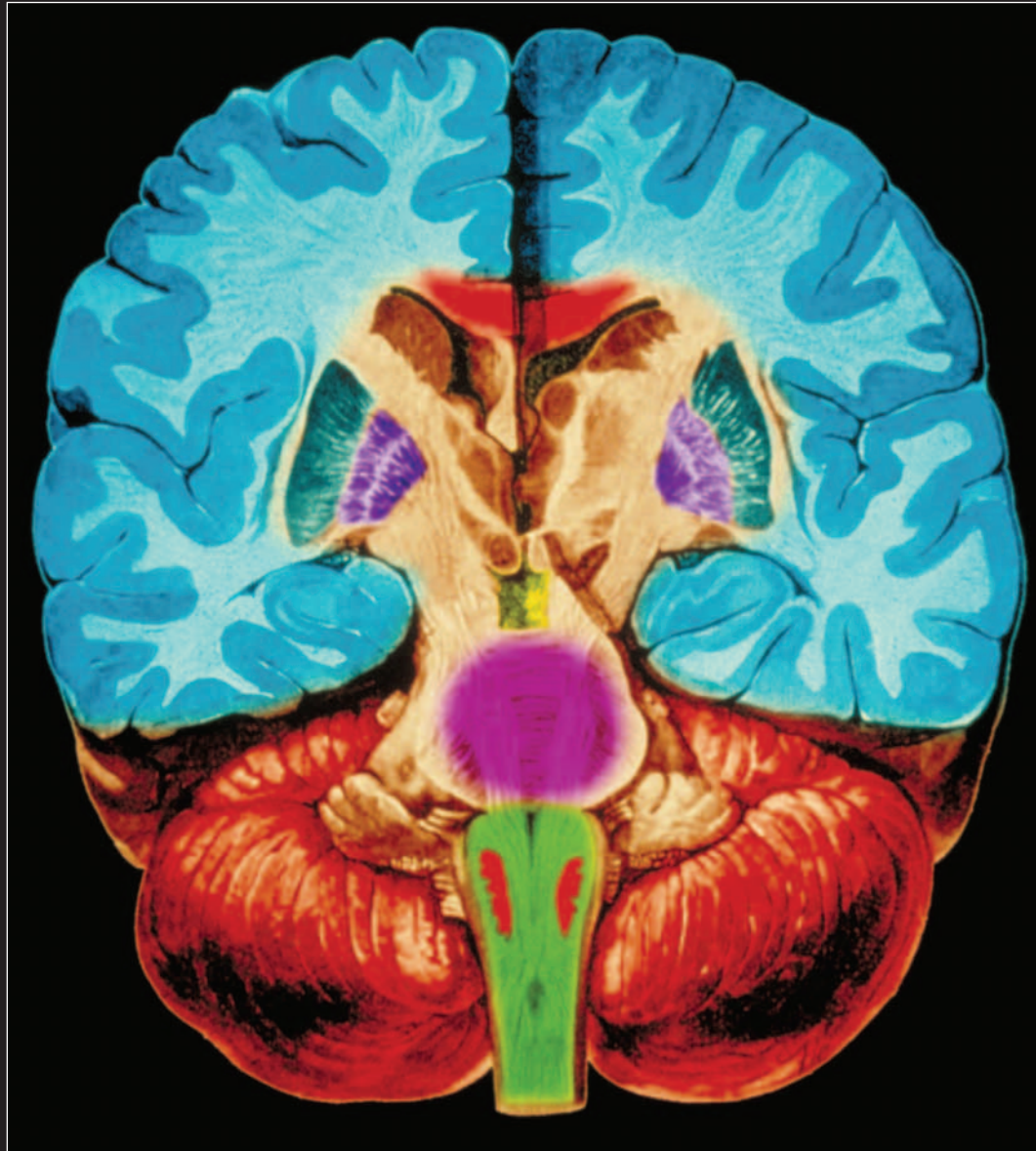



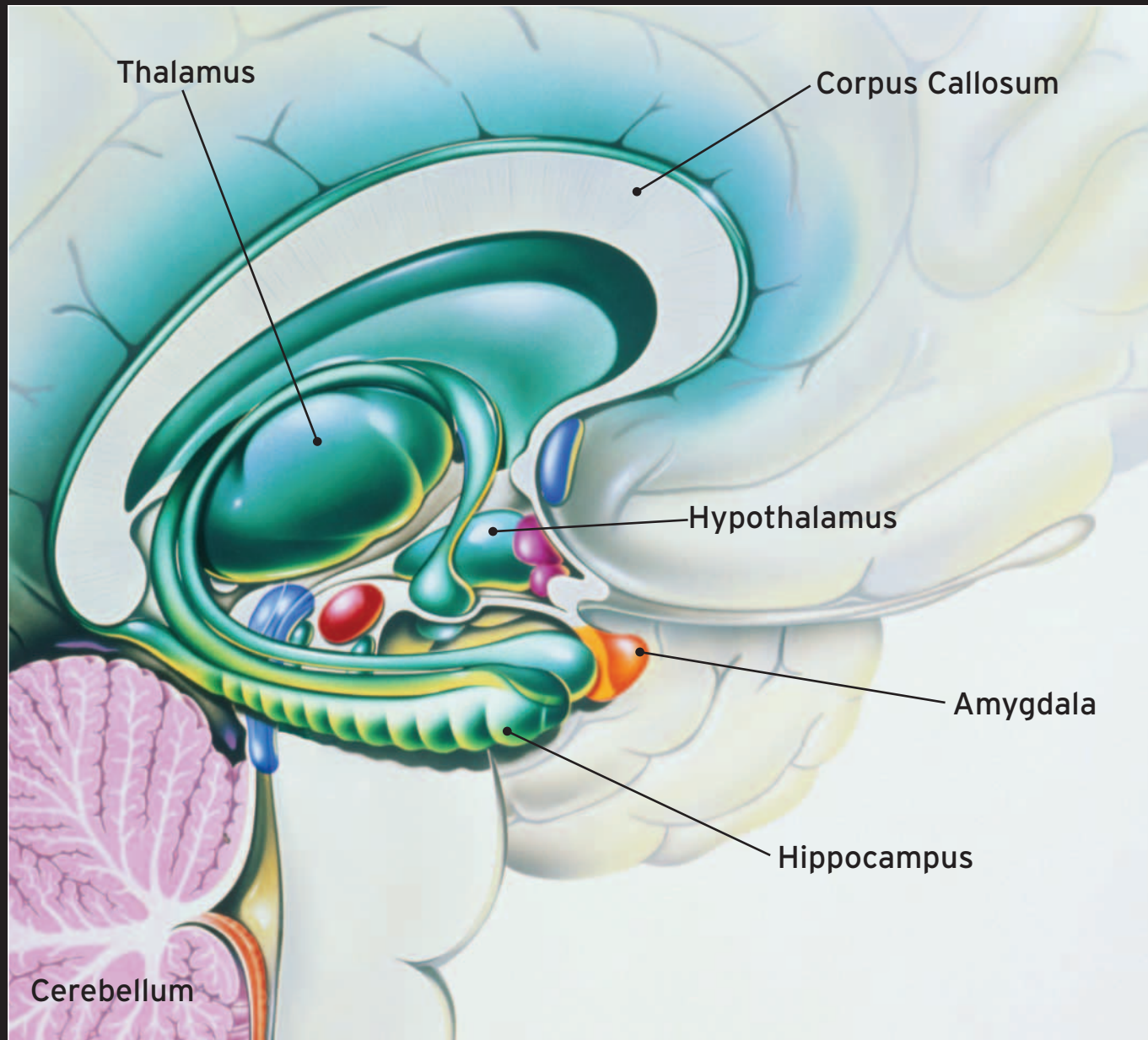
# Scan of the Brain from the Front



# Coronal Section of the Brain

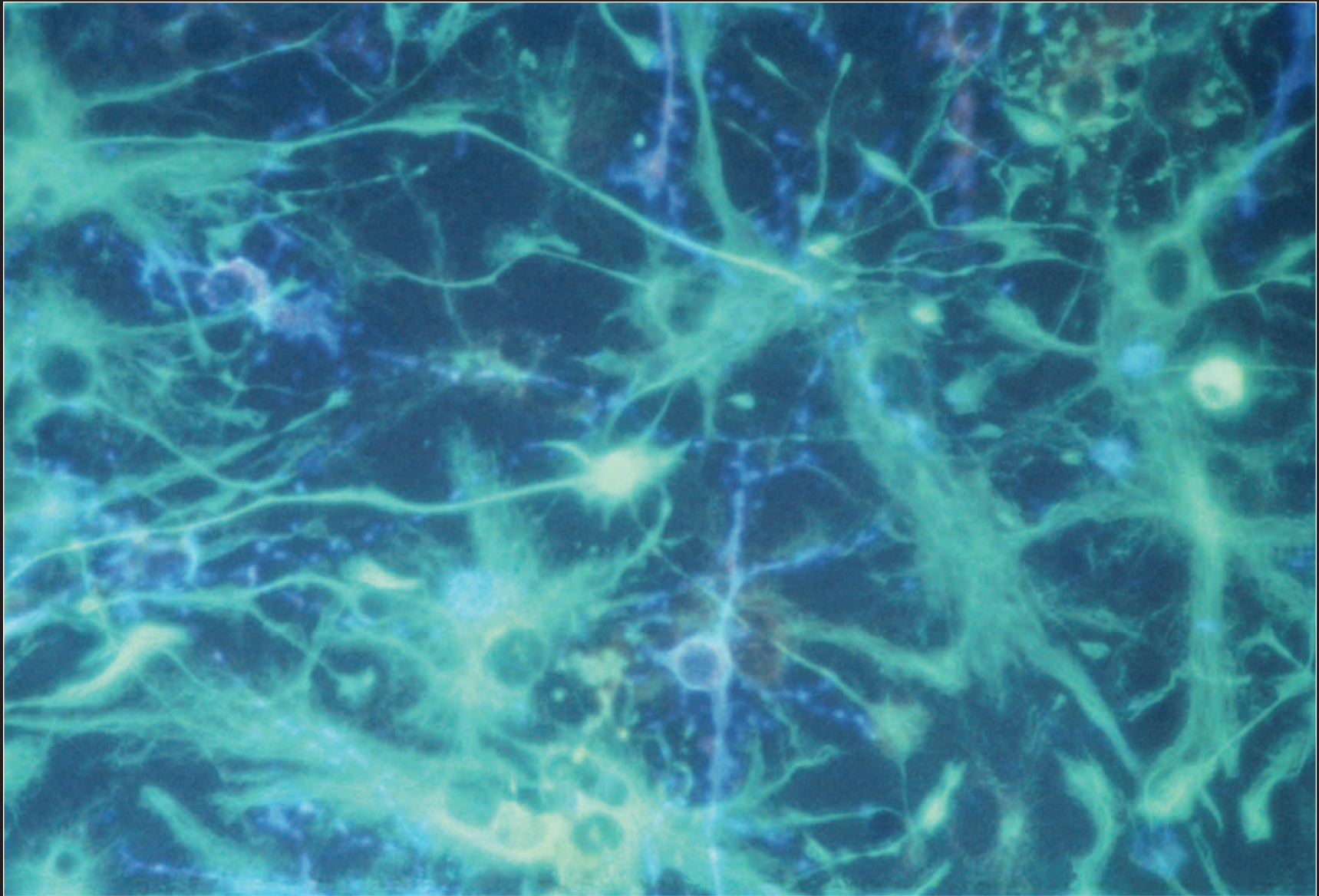


# Limbic System of the Brain

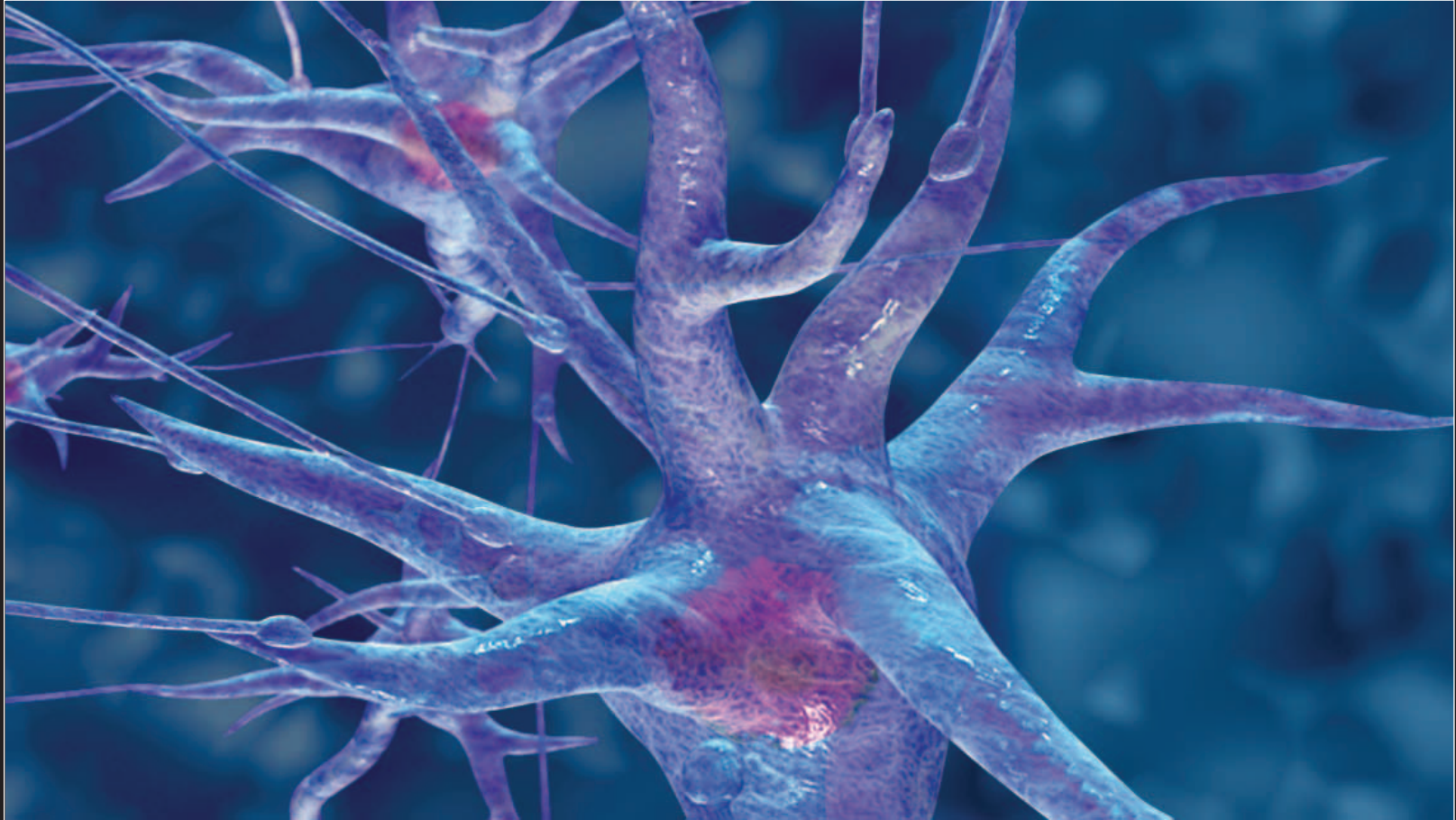




# Brain Cells in the Grey Matter

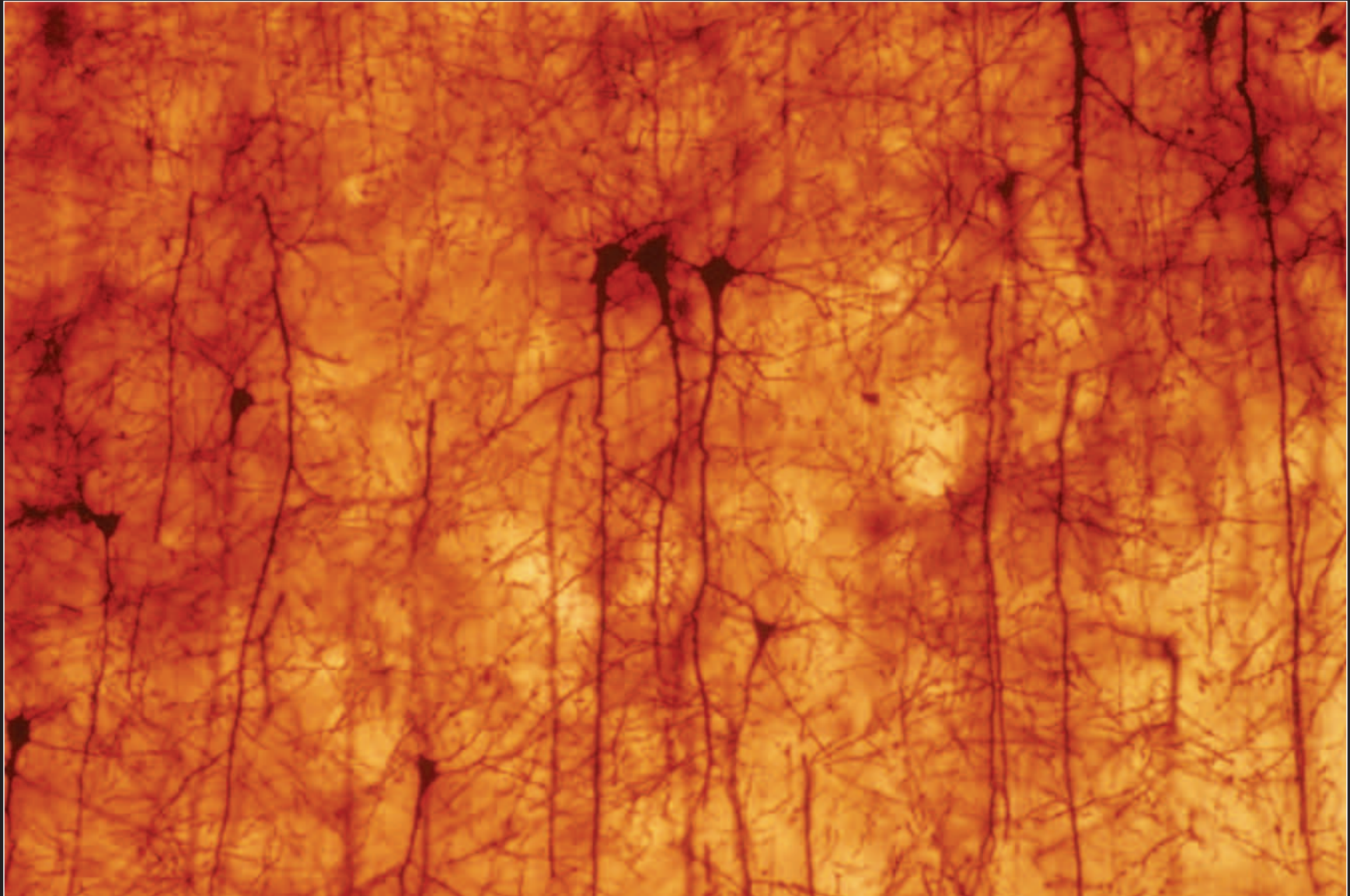


# Neurons Are Nerve Cells





# Nerve Cells of the Cerebral Cortex

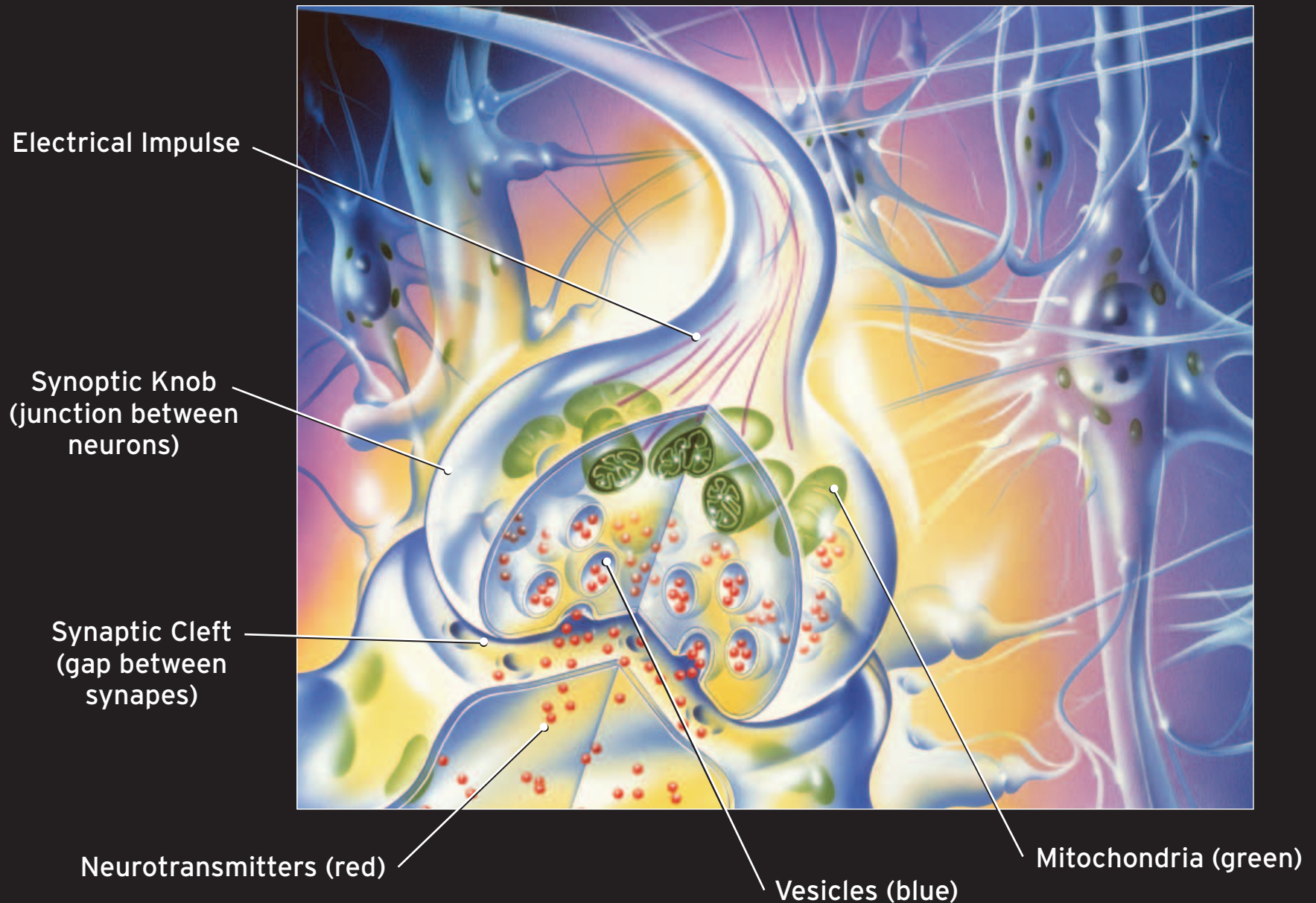


# Synapses Make Connections

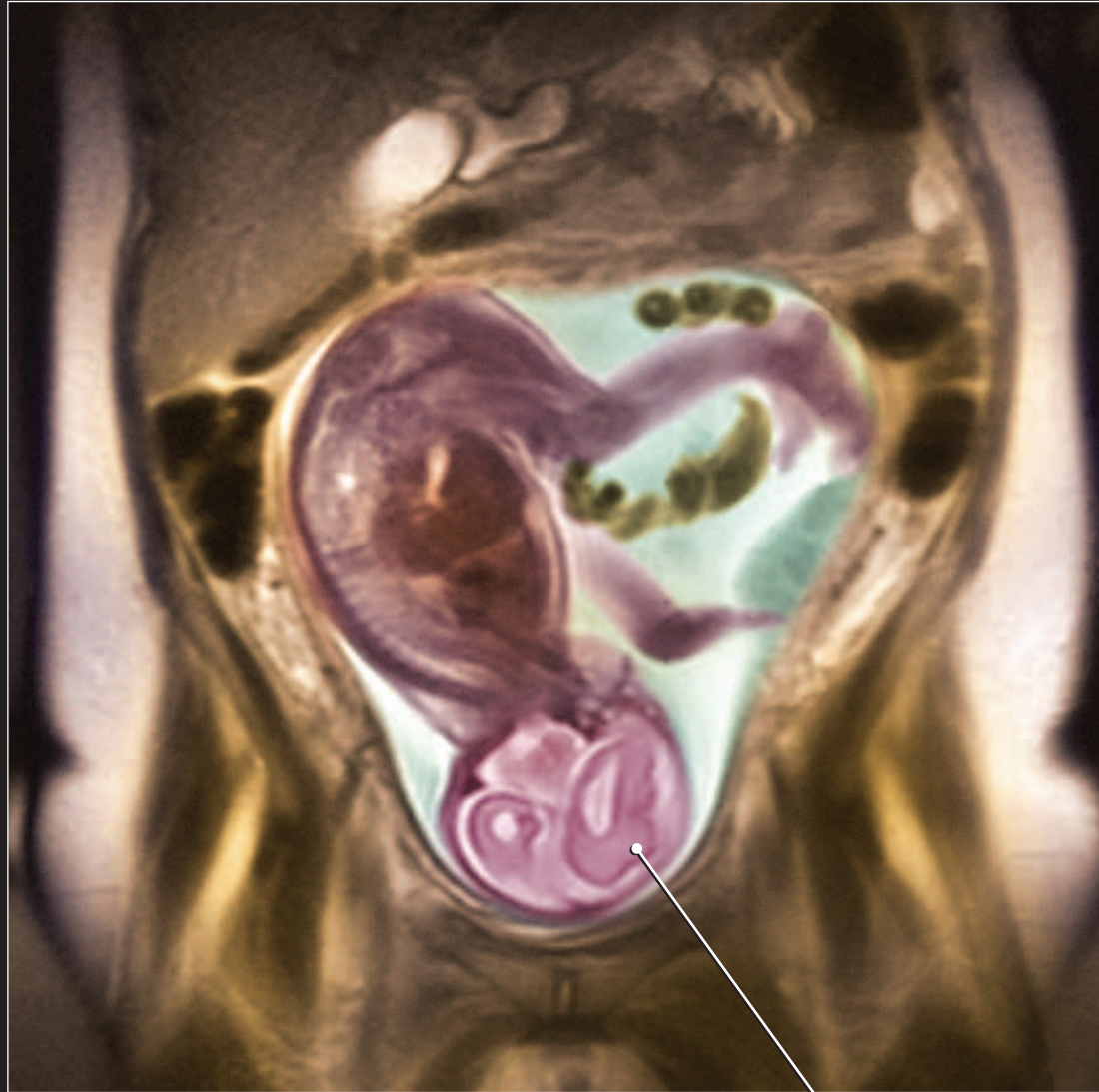




# Synaptic Junction Between Neurons



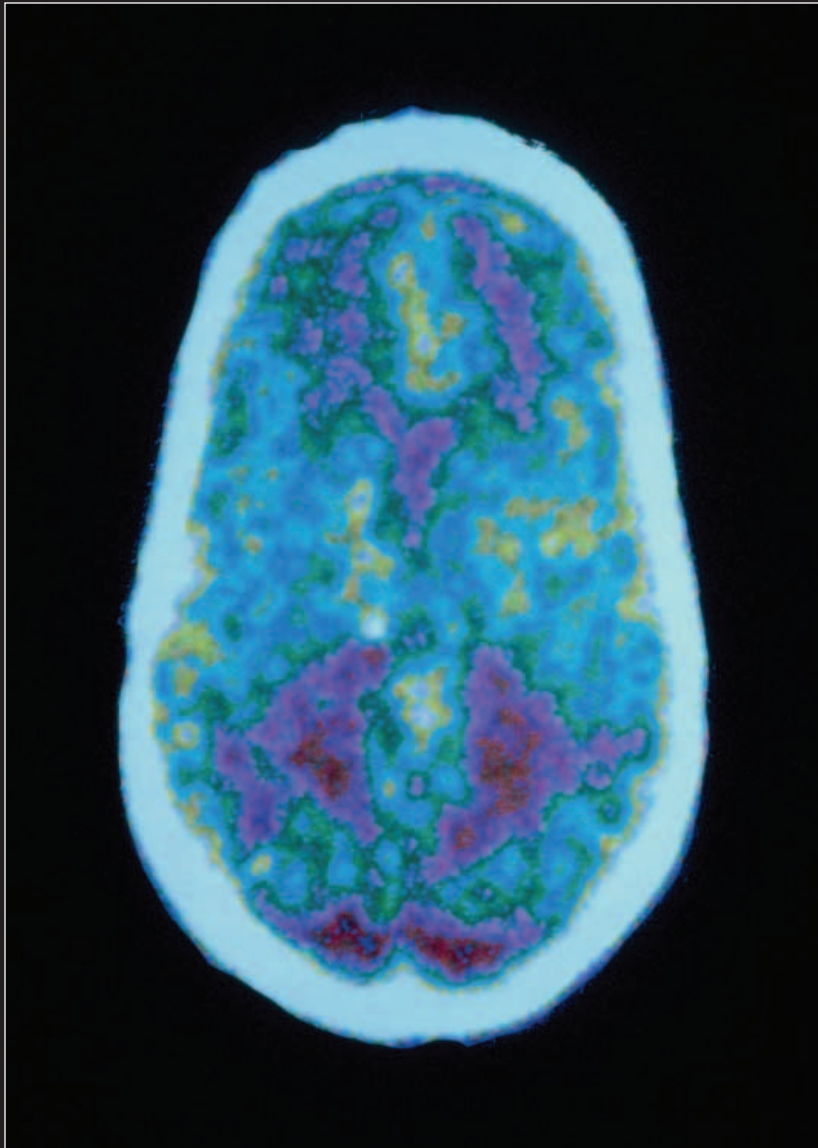
# The Developing Brain In Utero



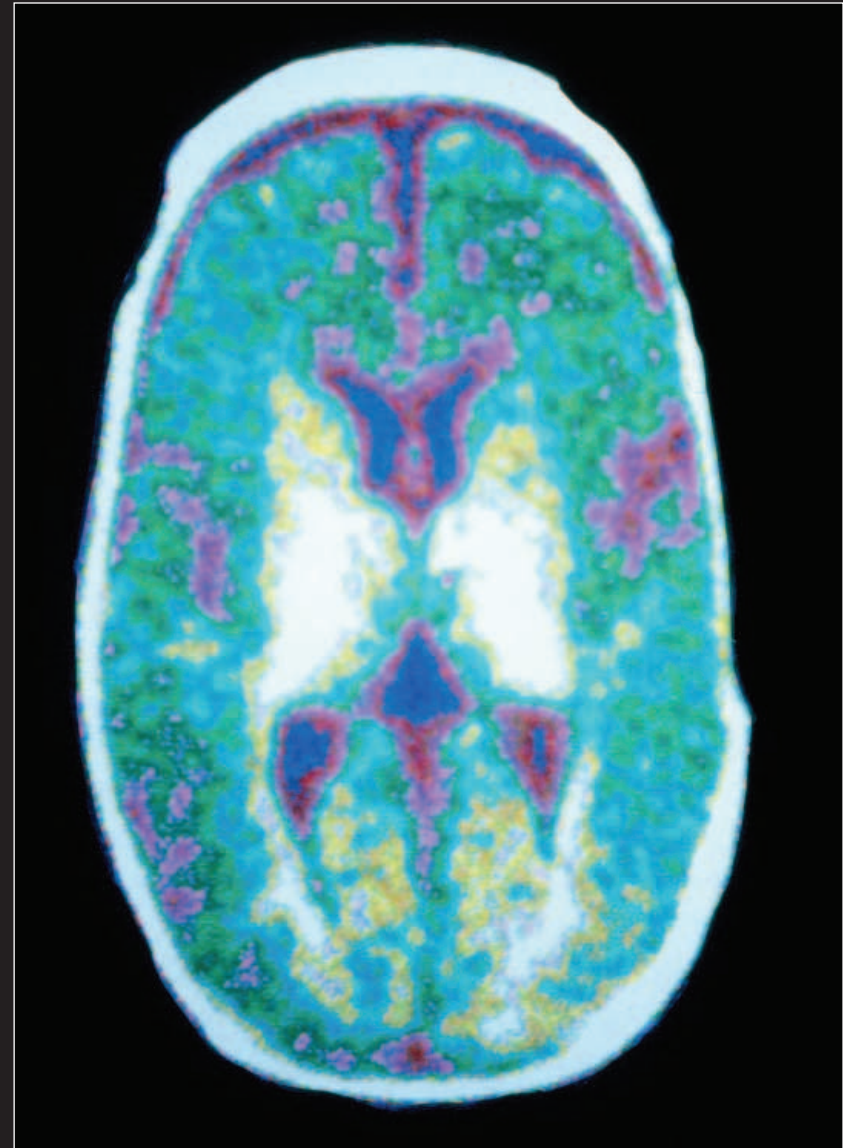
The Developing Brain



# Brain Development (Birth to 6 months)



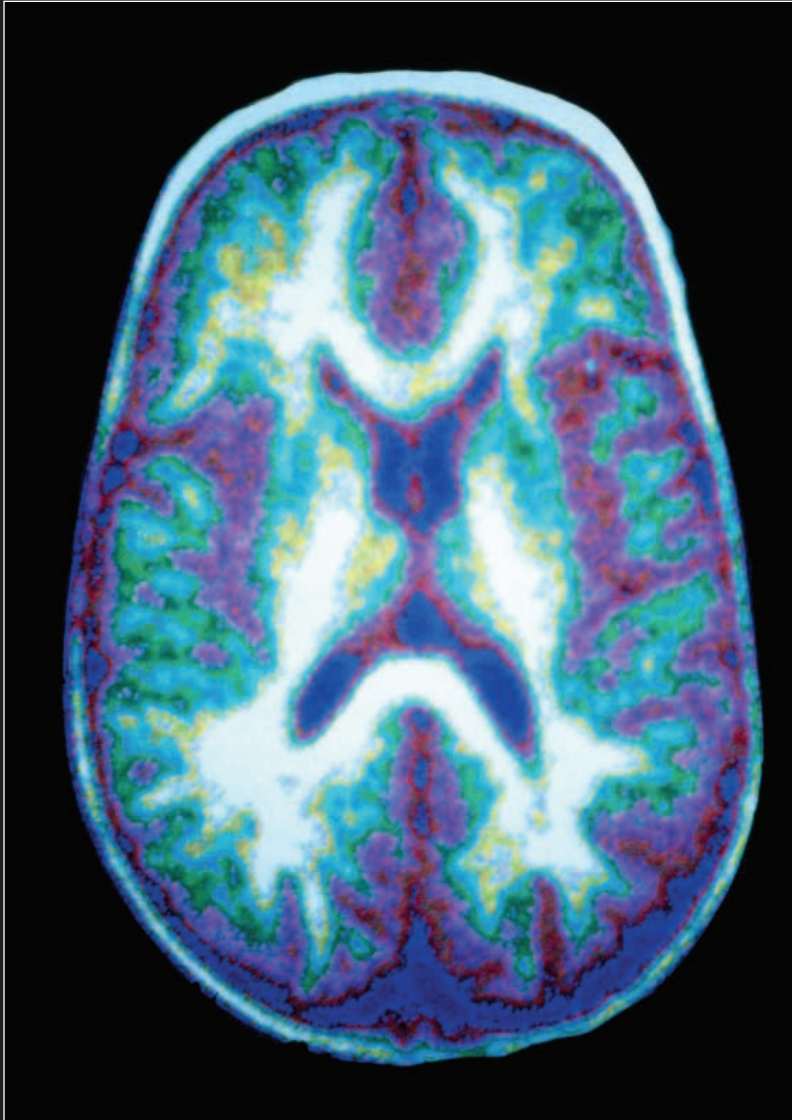
Newborn



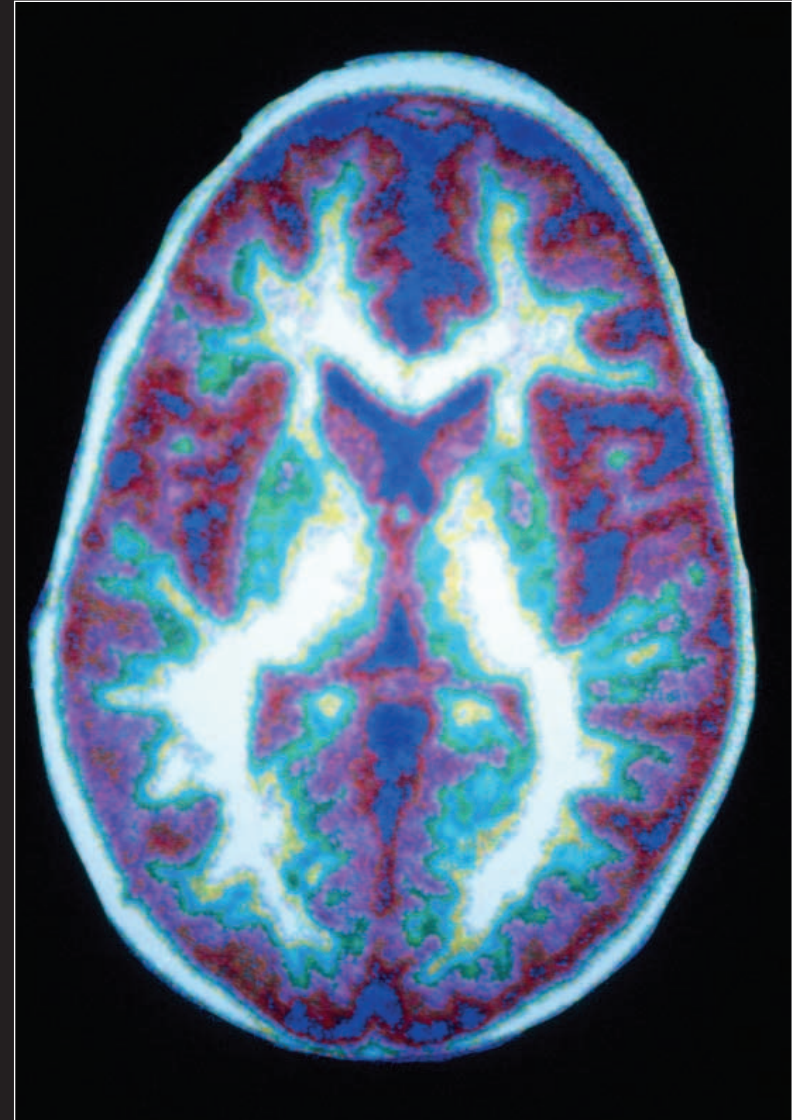
6 months



# Brain Development (20 months to 5 years)

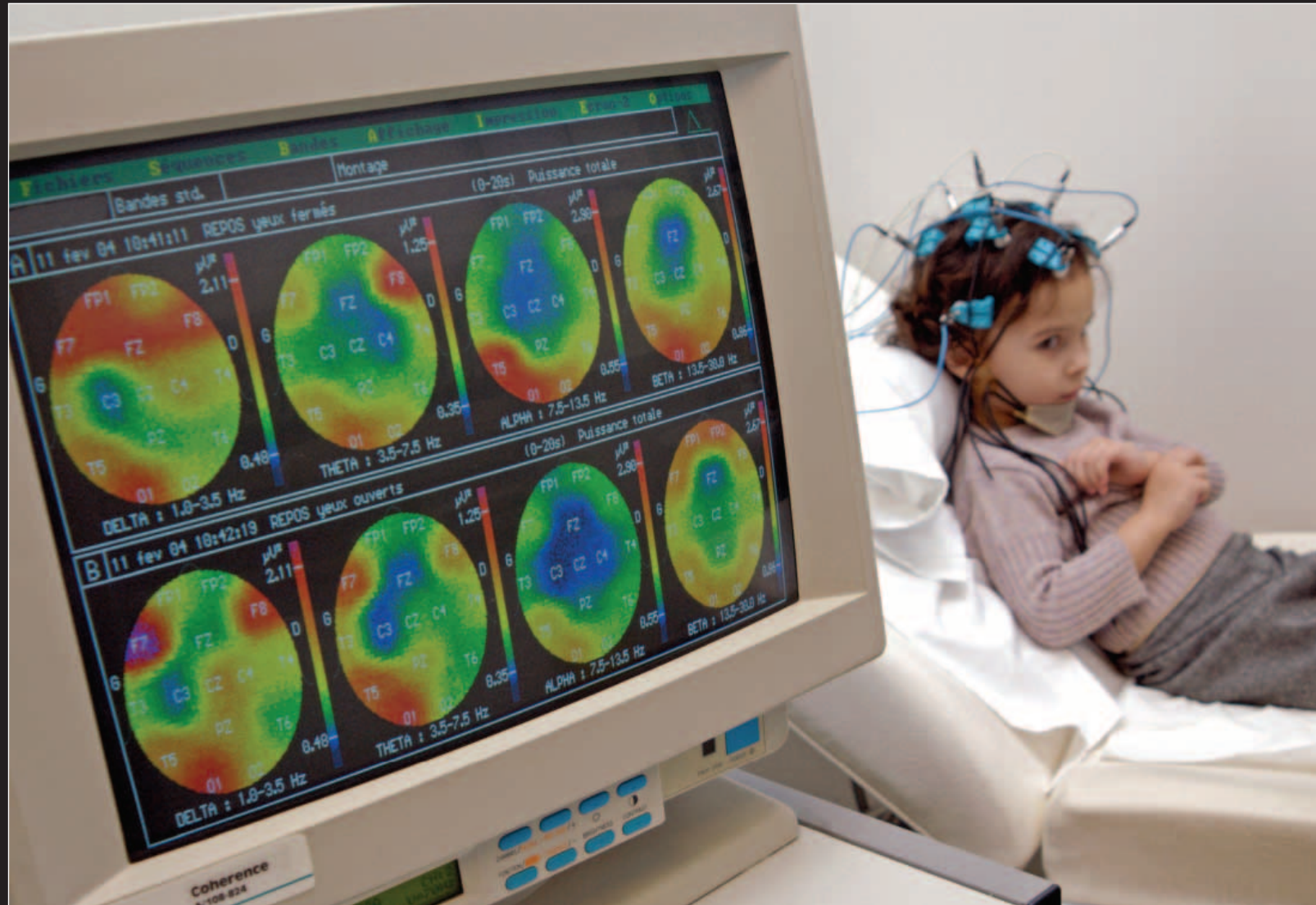


20 months



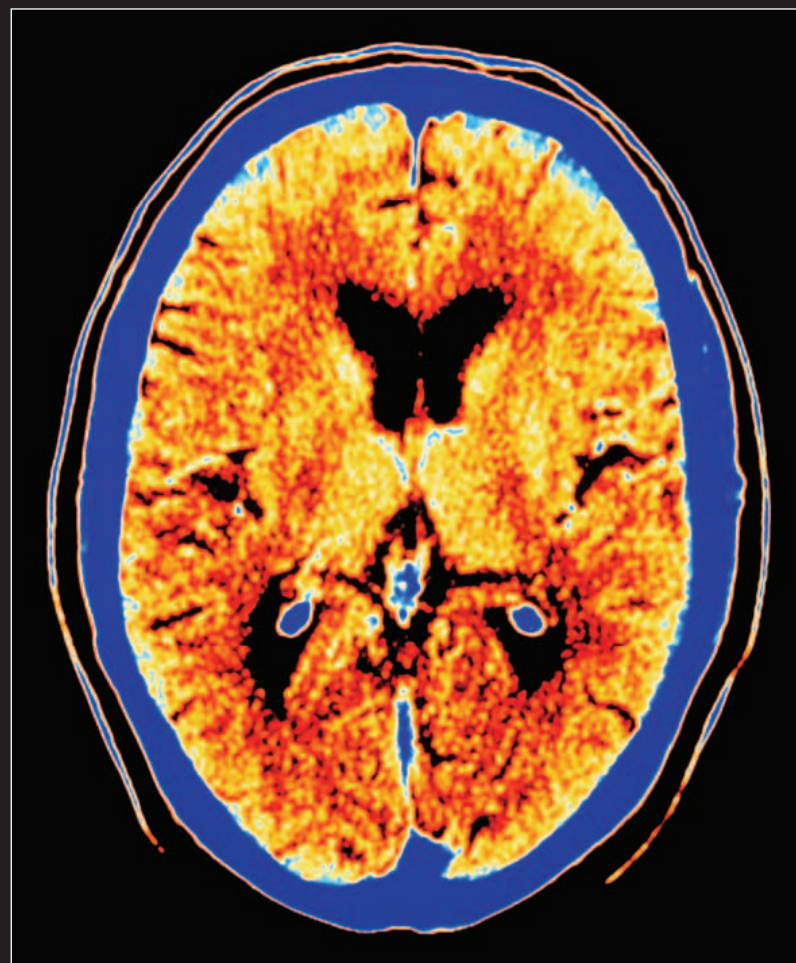
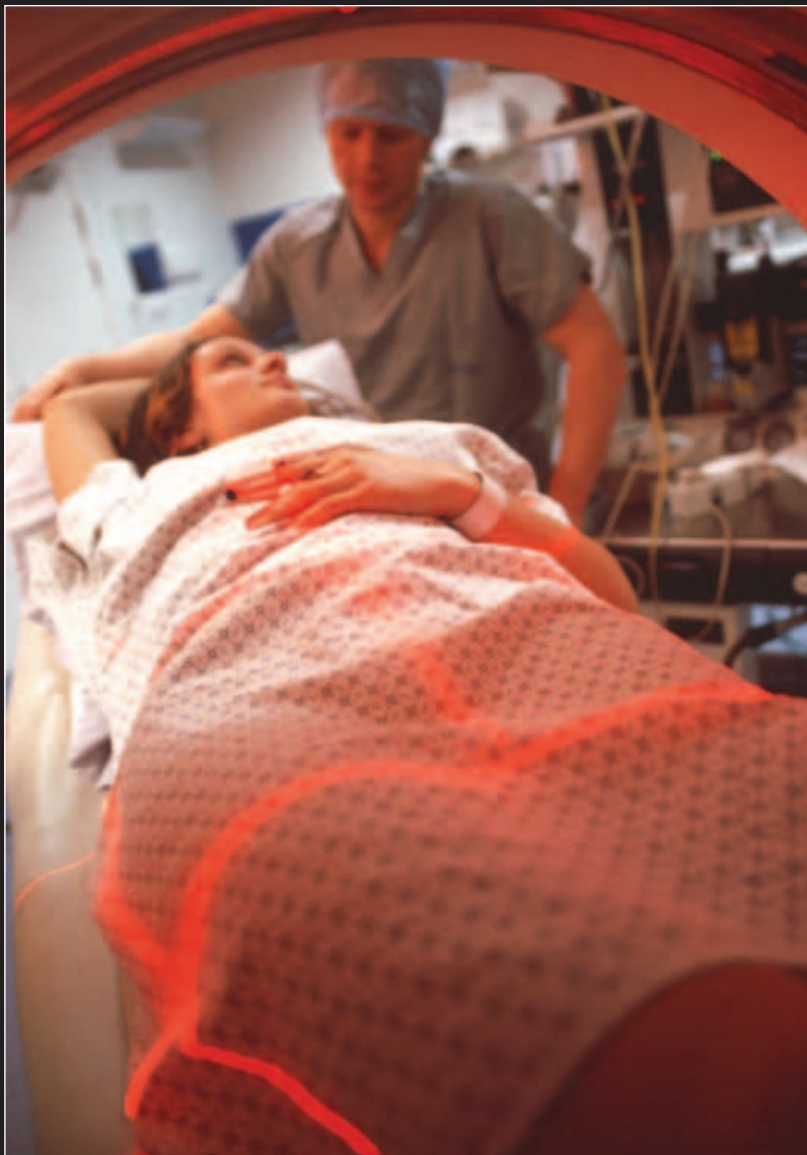5 years

# Electroencephalogram (EEG)



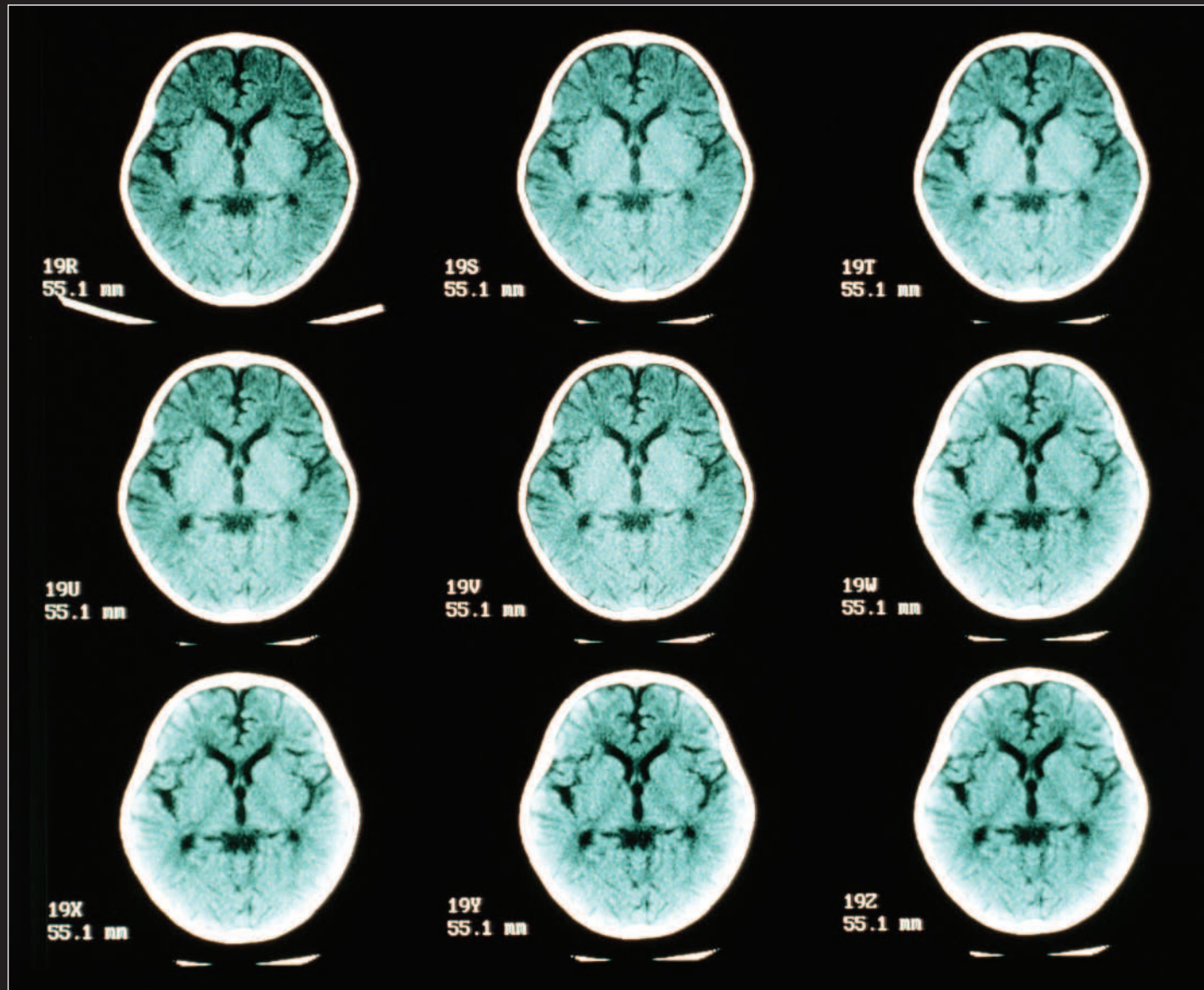


# Computed Tomography (CT) Scan



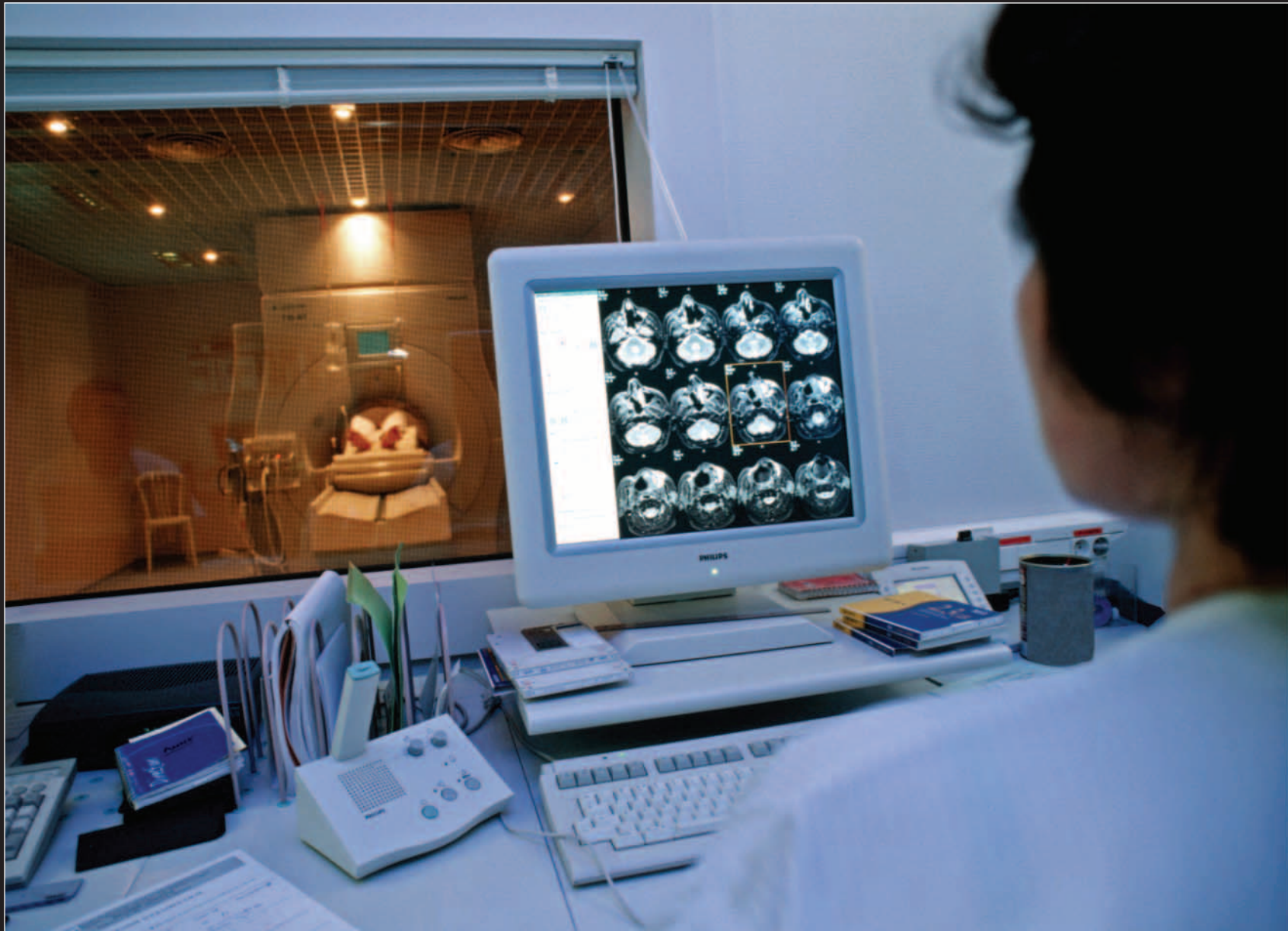Front of Brain

# CT Scan of Healthy Brain (Axial Section)



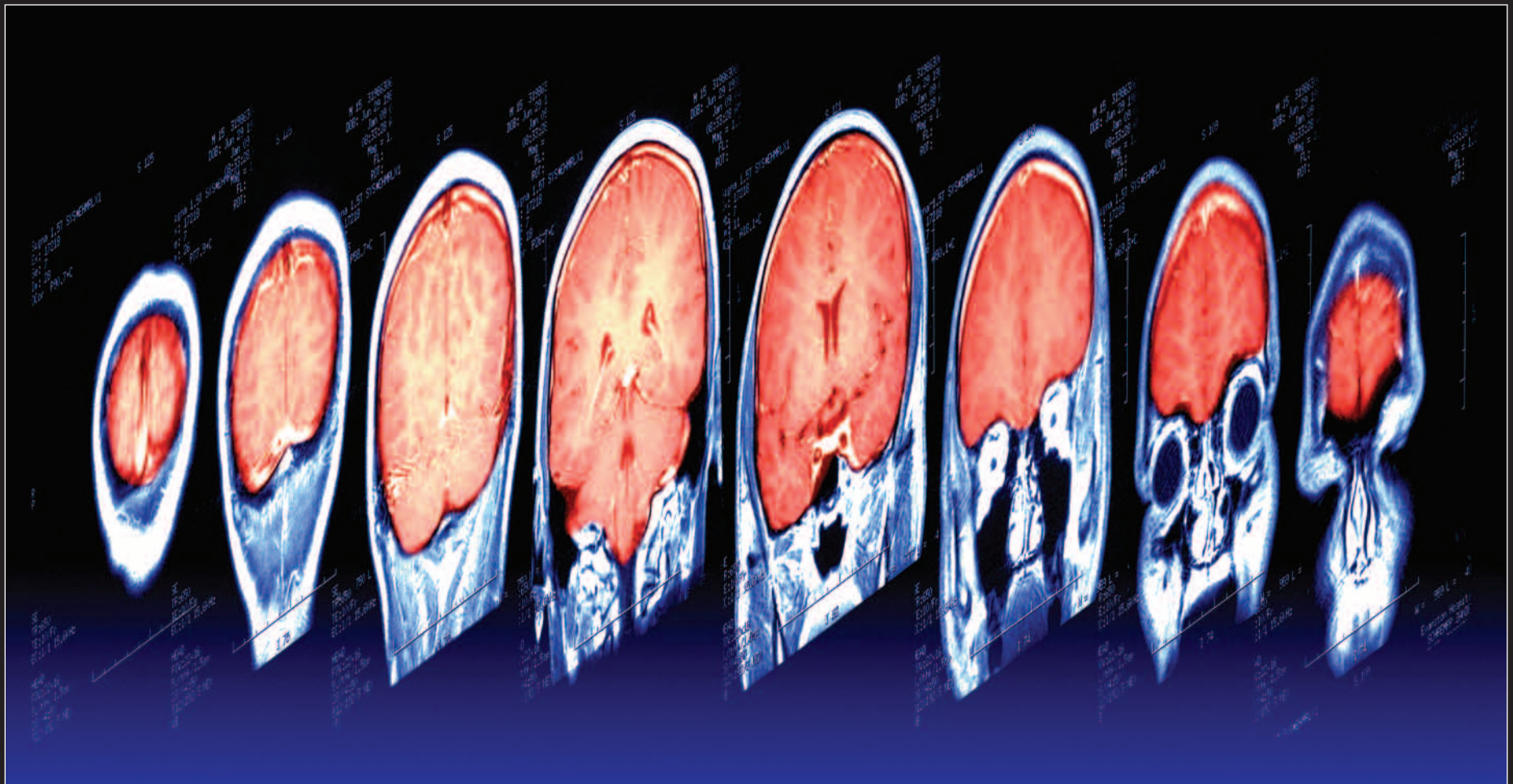


# Magnetic Resonance Imaging (MRI) Scan

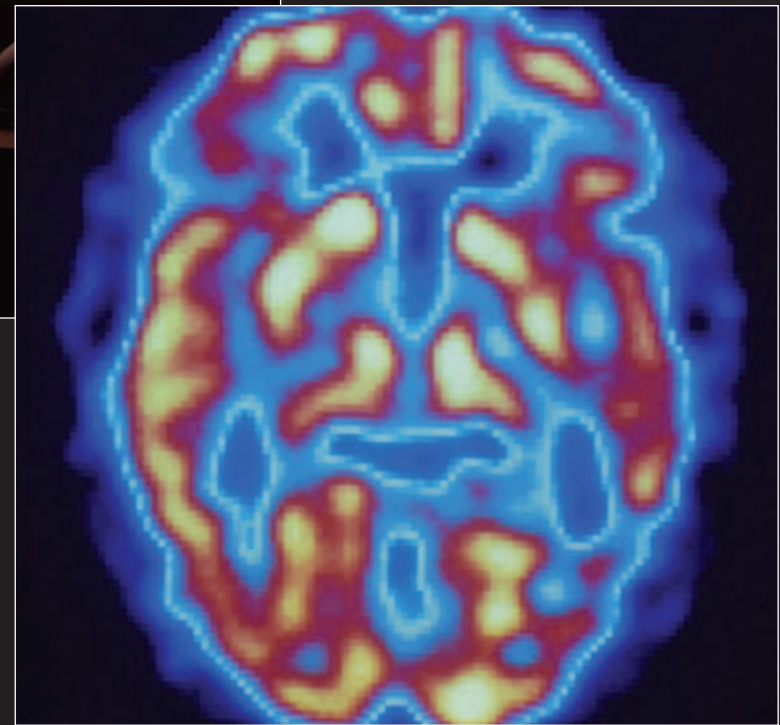
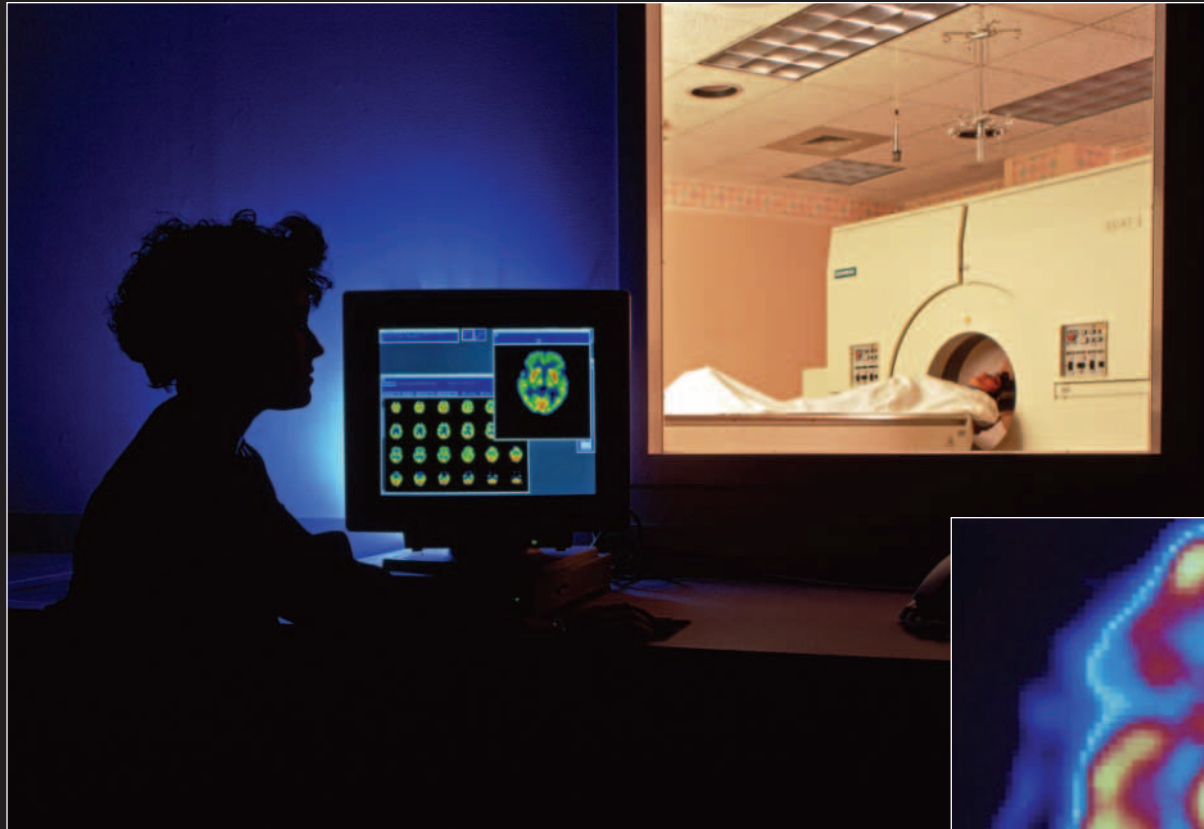



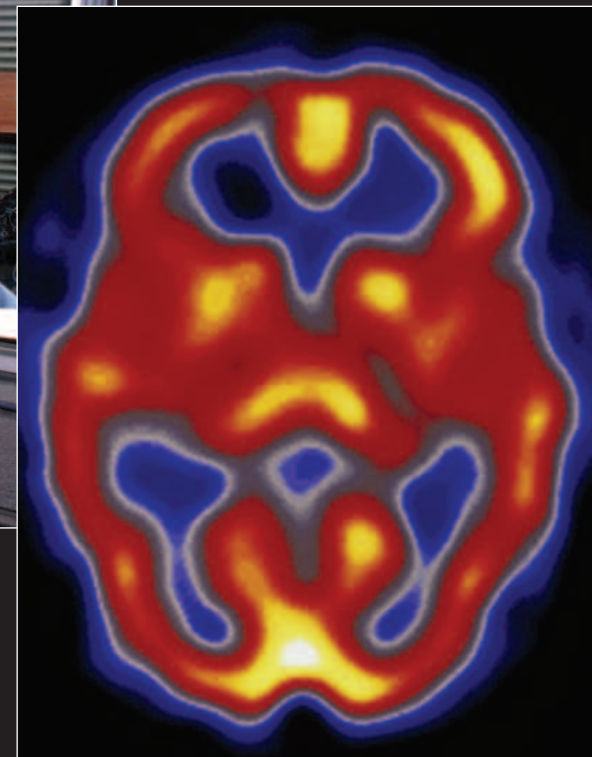
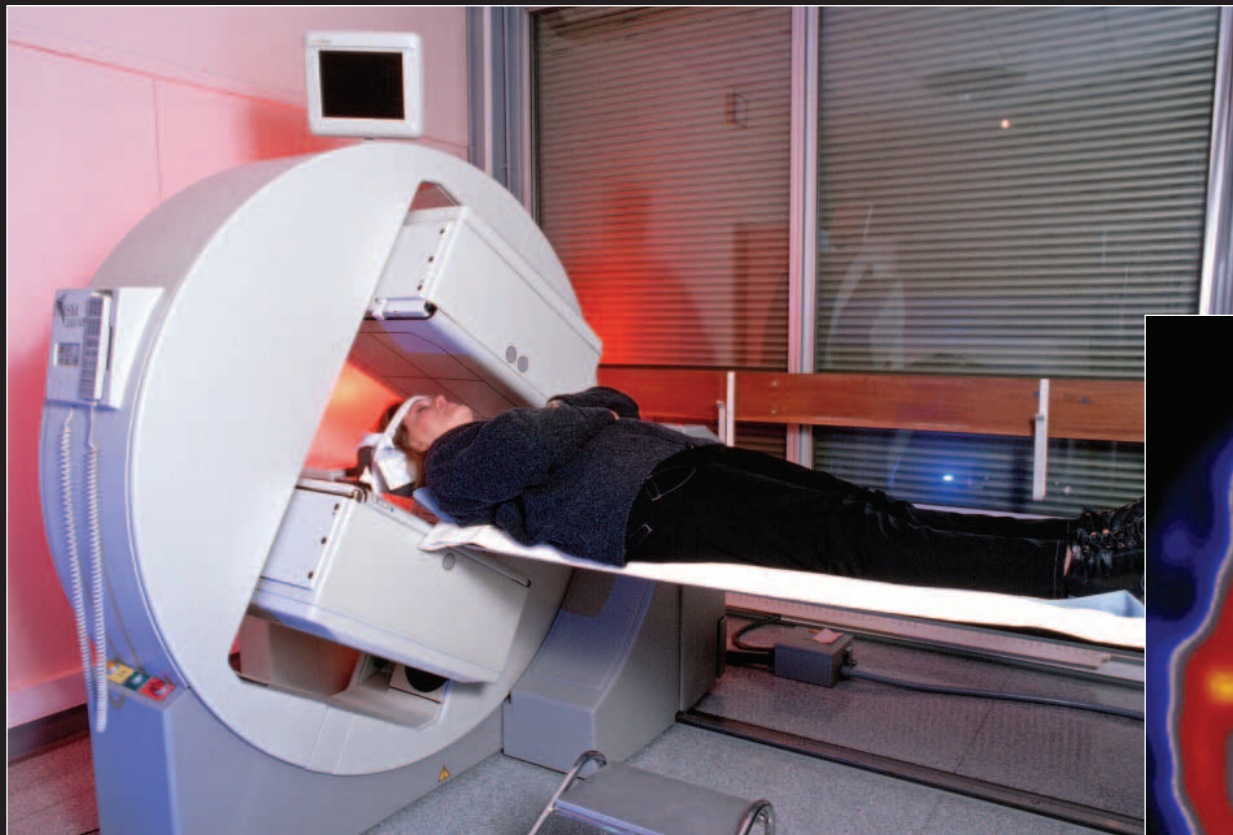
# MRI Head Scan Showing Slicing Nature of MRI Imaging



# Positron Emission Tomography (PET) Scan

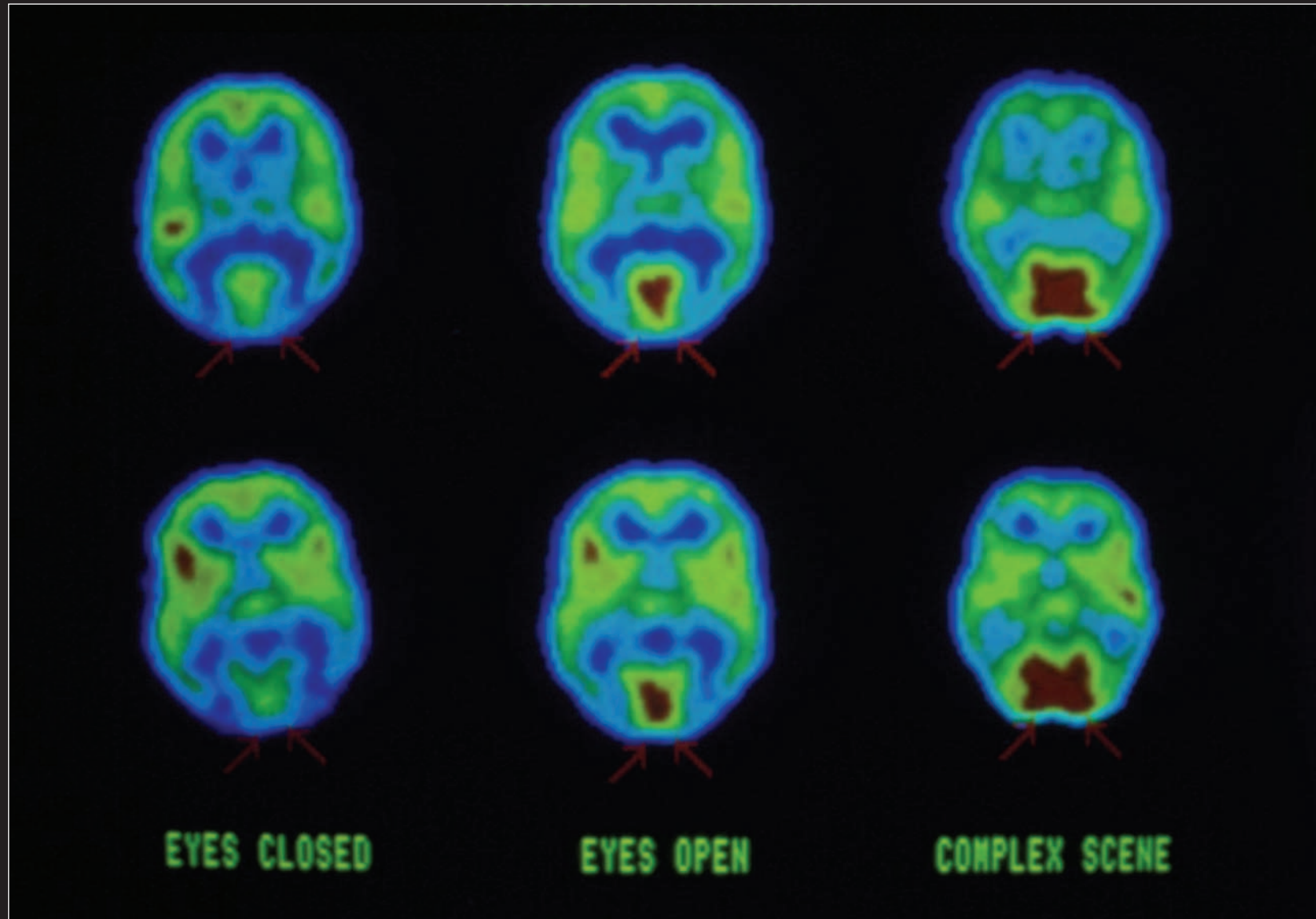


# Single-Photon Emission Computed Tomography (SPECT) Scan

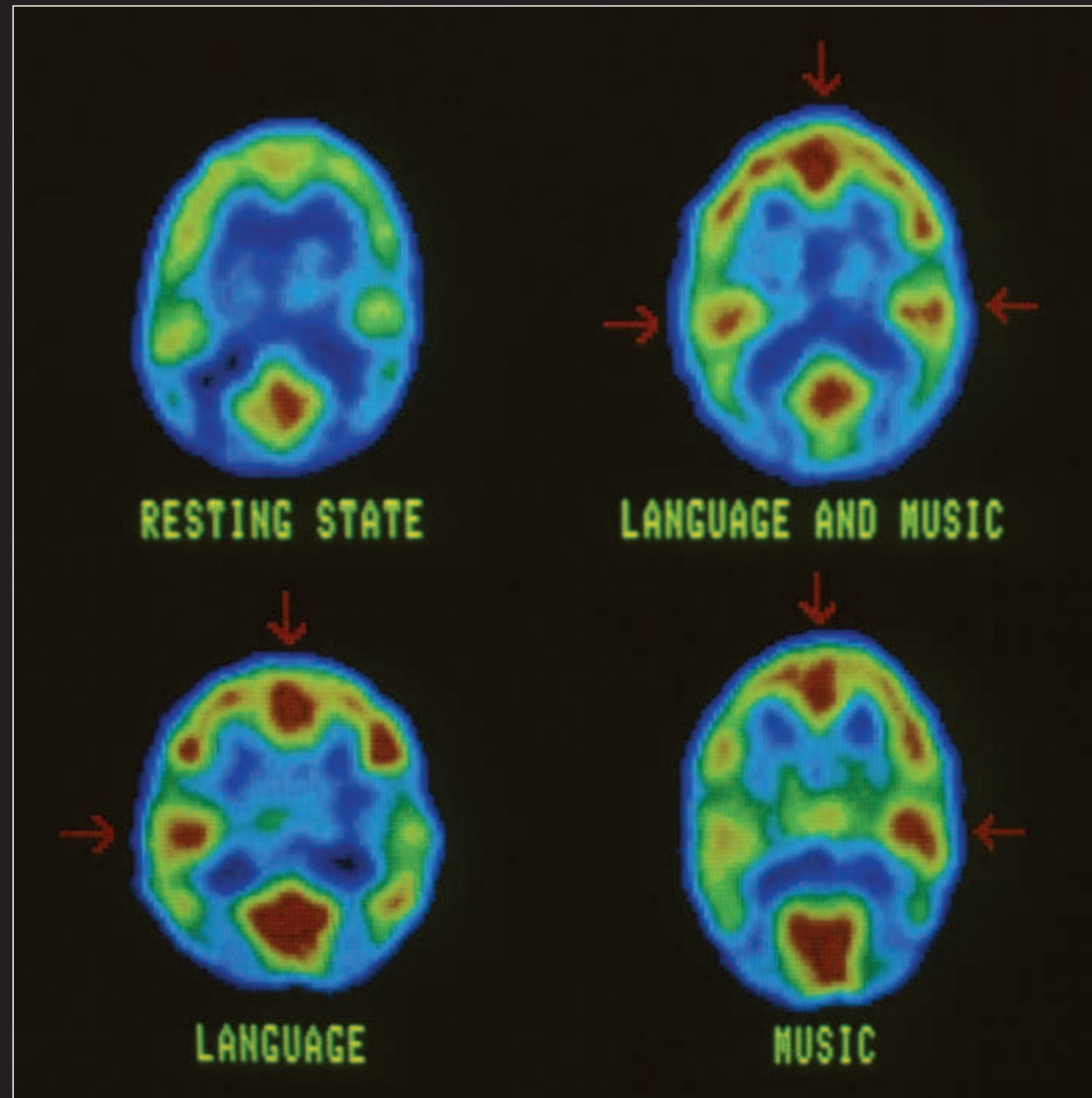




# Positron Computed Tomography (PCT) Scans of Visual Stimulation

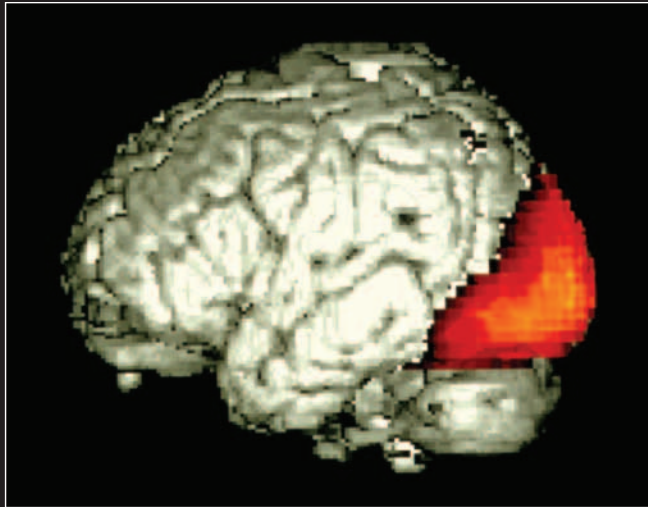


# Positron Computed Tomography (PCT) Scans of Auditory Stimulation

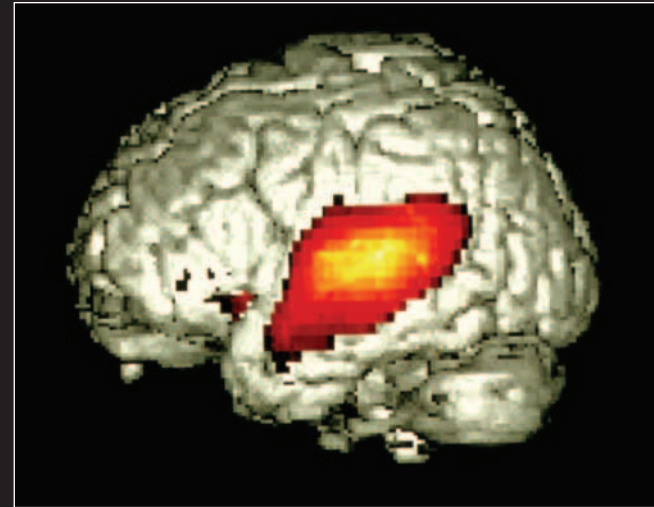




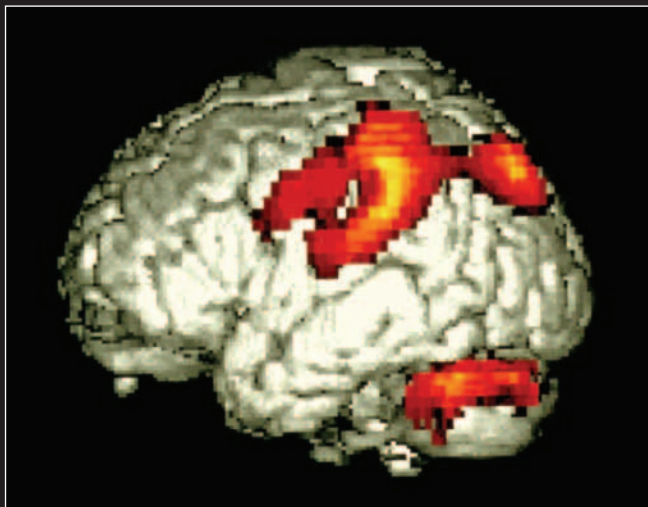
# Activity Areas in the Brain



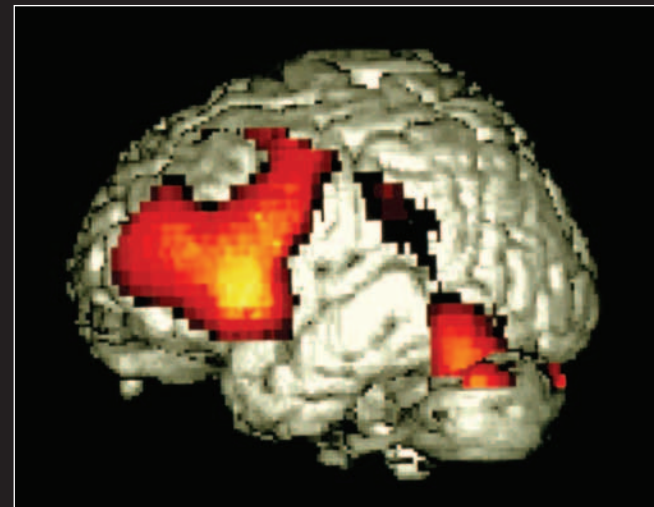
Sight activates the occipital cortex.



Hearing activates the temporal cortex.

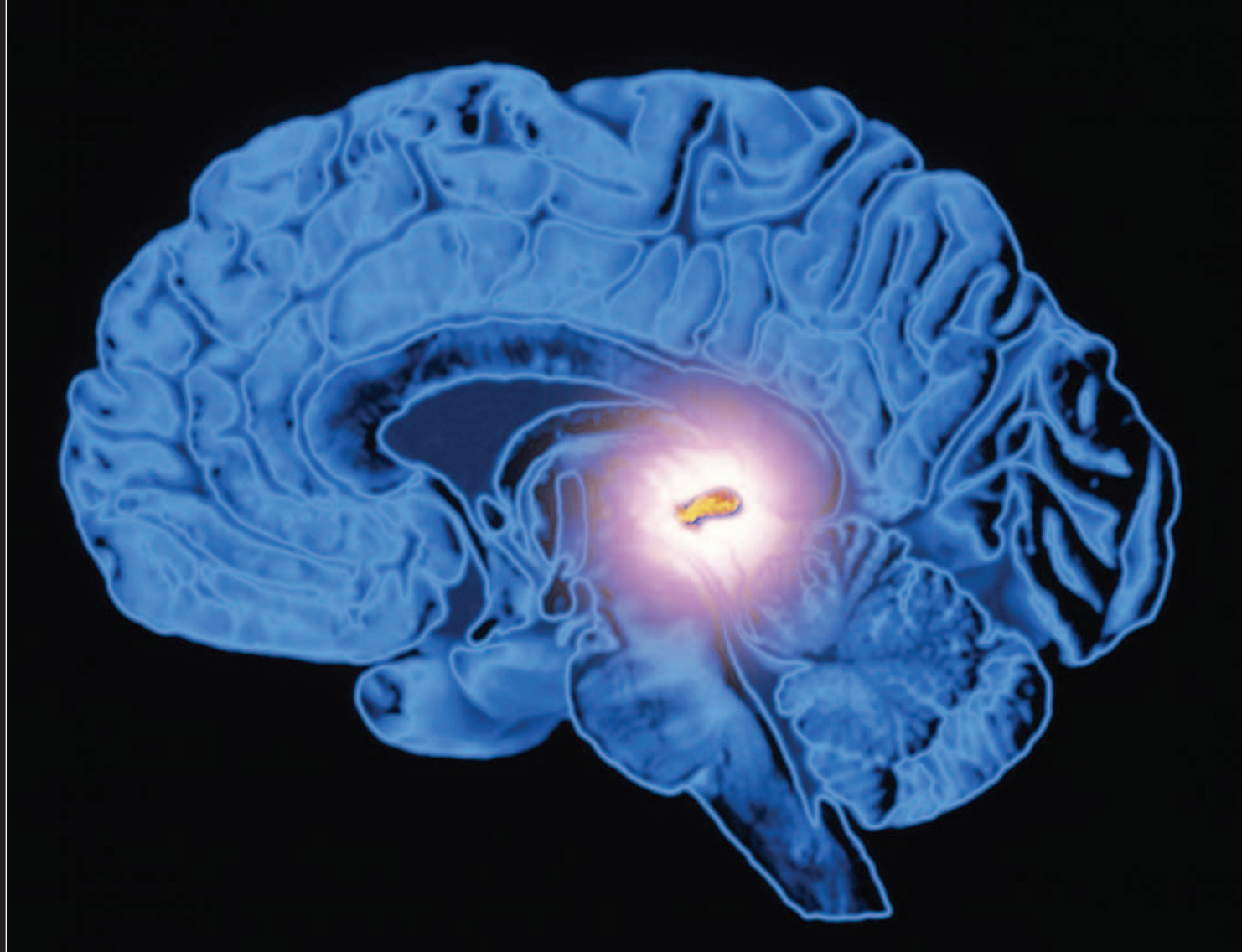


Touching braille script activates the tactile parietal area and cognition (lower right).

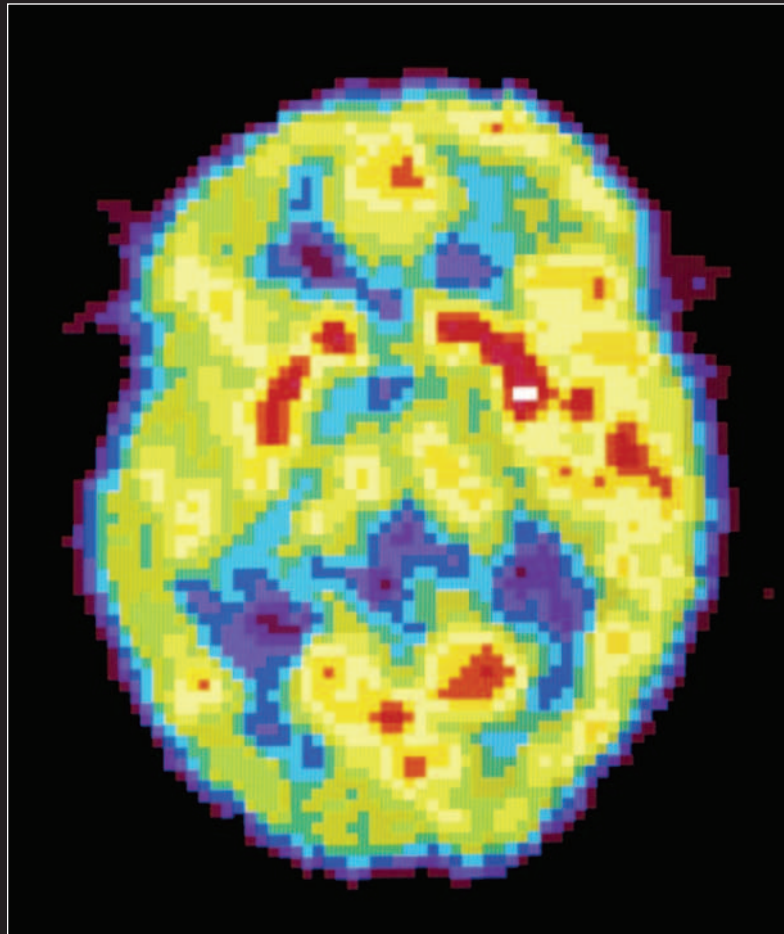


Thoughts in the frontal cortex are used to generate words.

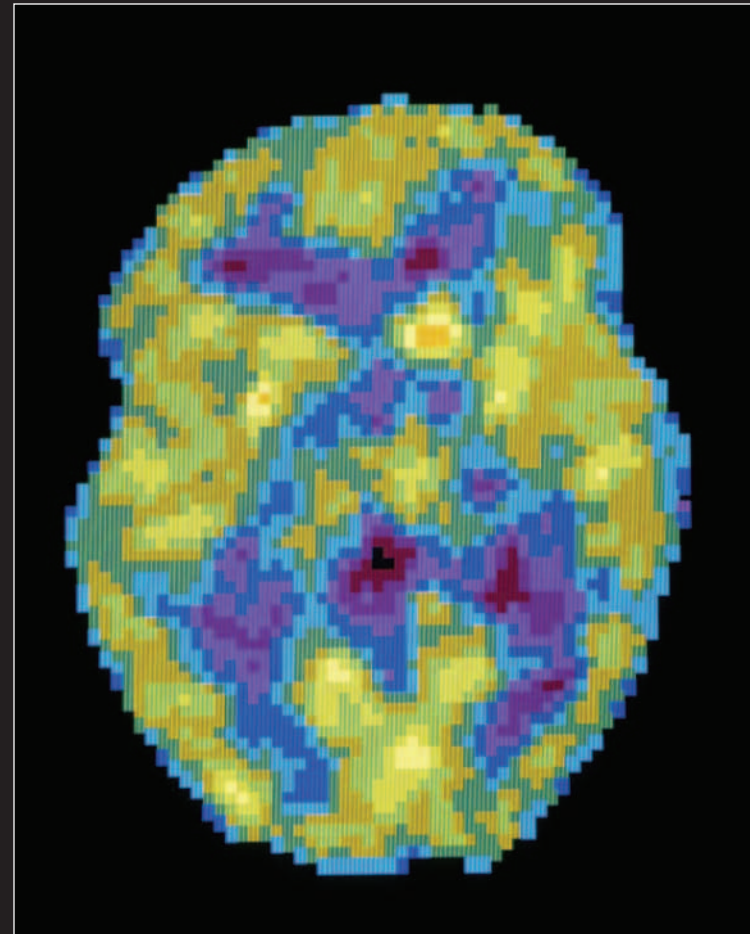
# Pineal Gland



# PET Scans During Sleep



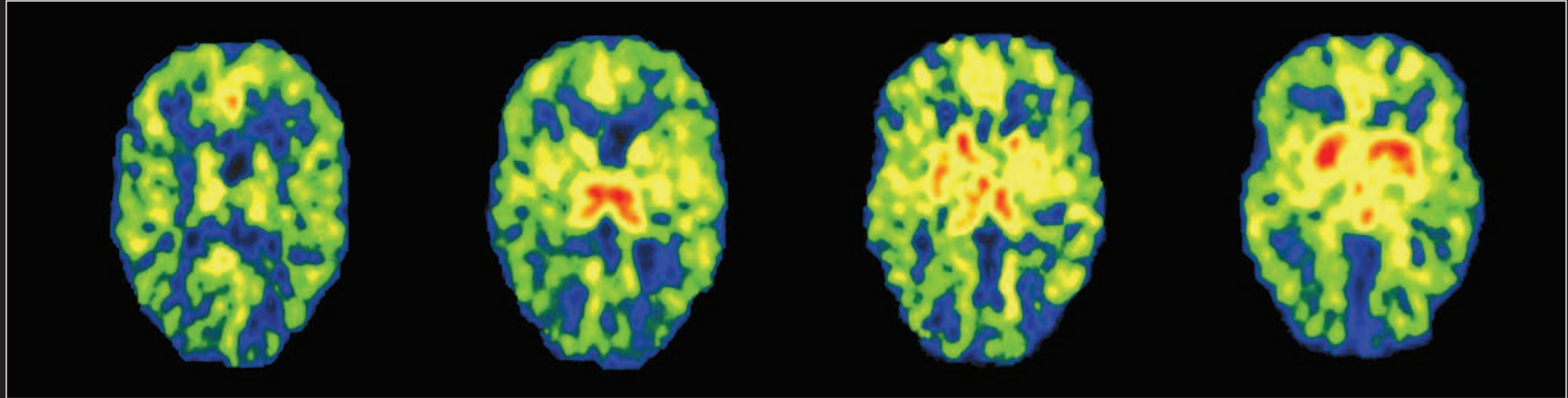
Normal Sleep



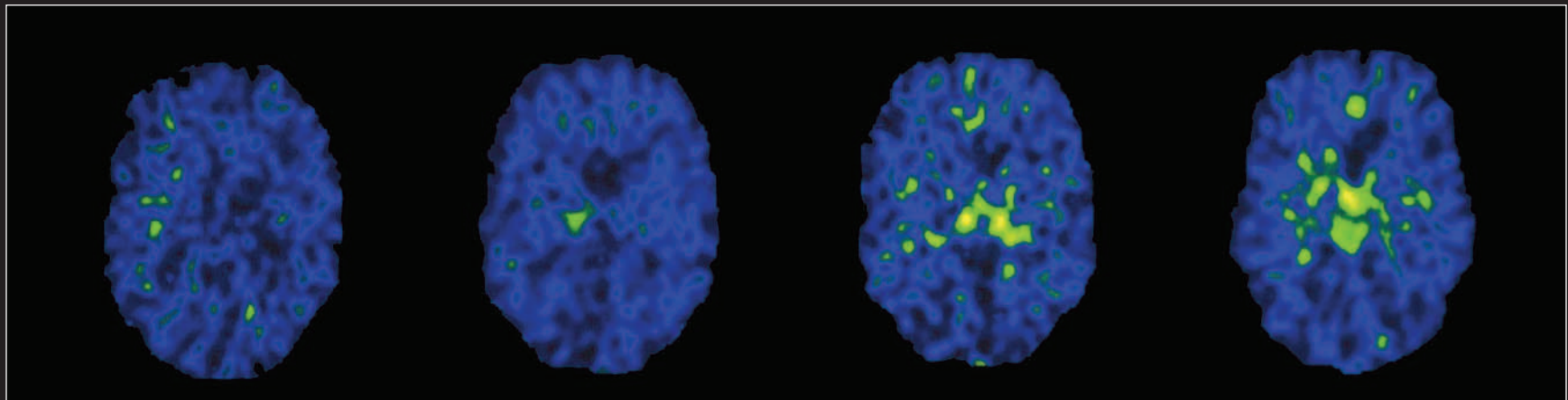
Sleep Deprivation



# PET Scans Showing MAO B (red) and Dopamine Levels (blue)



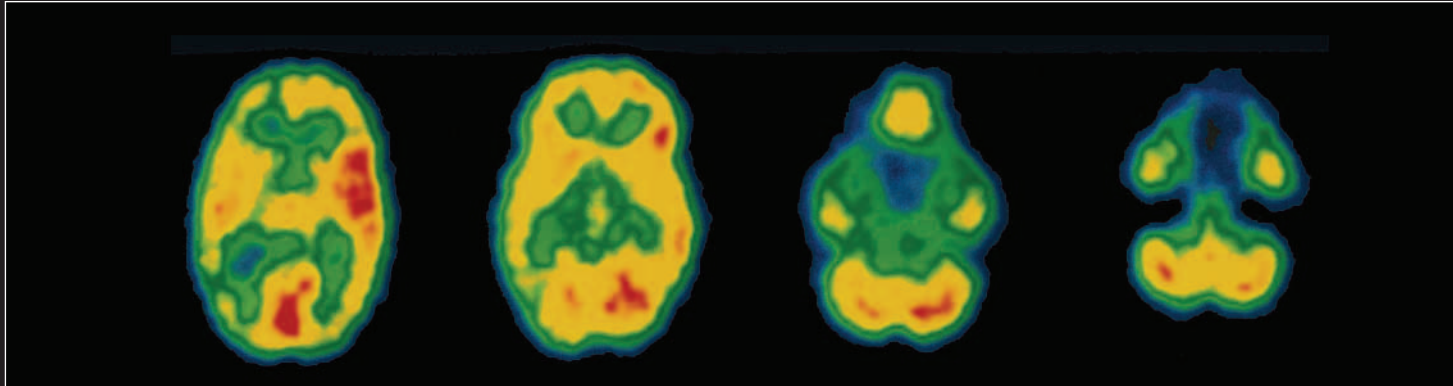
Non-Smoker (Male, 44-Years-Old)



Smoker (Male, 44-Years-Old)

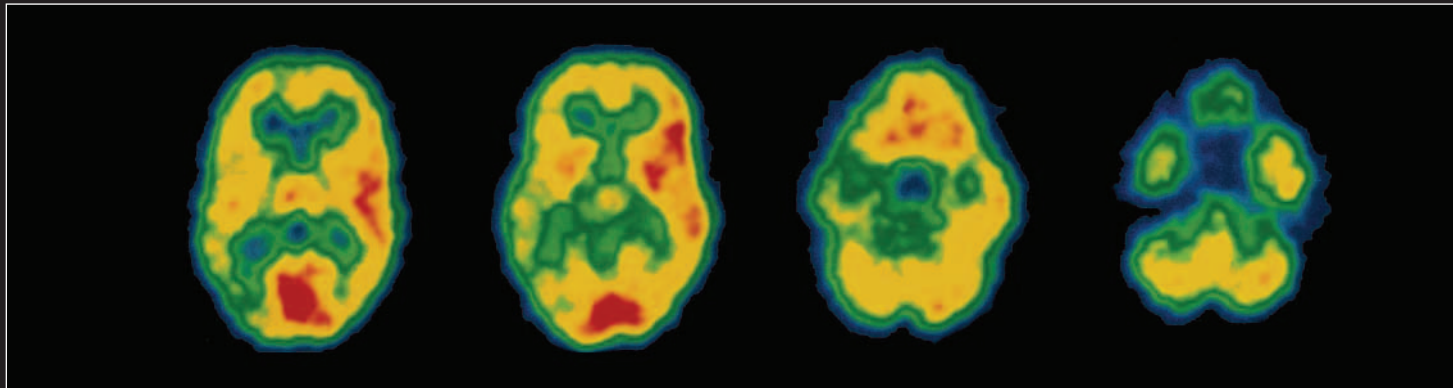


# PET Scans of the Effects of THC on Cerebellum Activity



**Non-User**

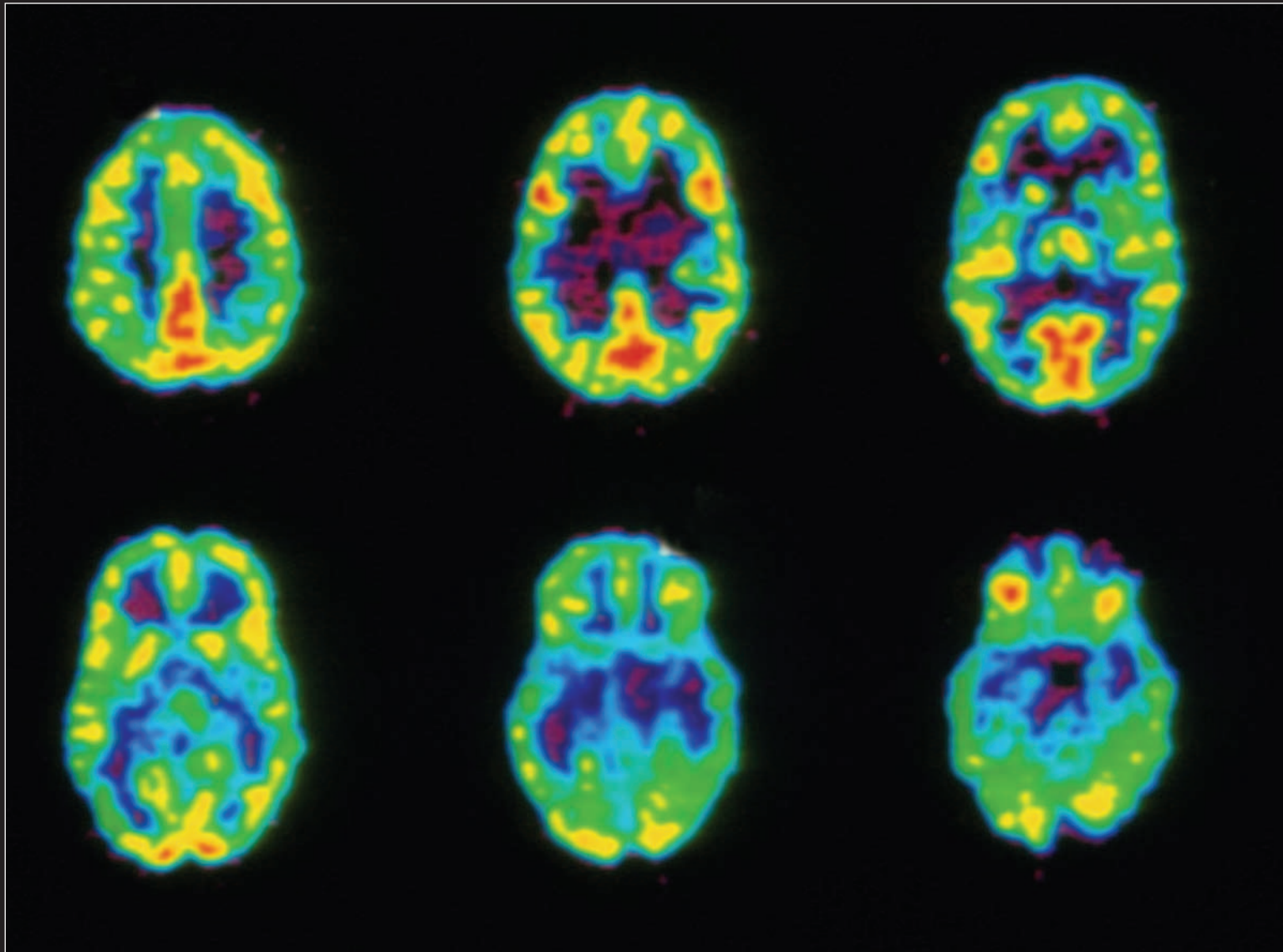
(Slices shown progressively deepen from left to right.)



**Marijuana Abuser**

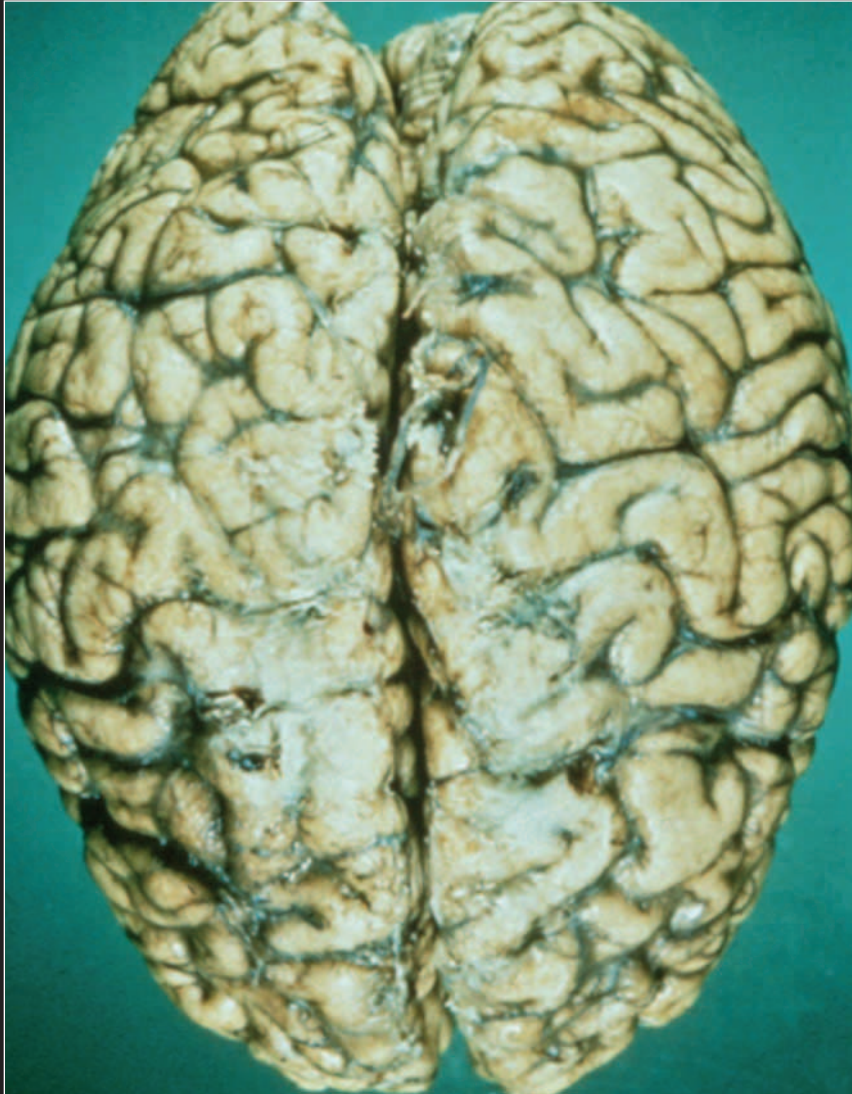(THC reduces the red areas of activity in the cerebellum— lower parts of each scan.)

# PET Scans of a Cocaine User's Brain

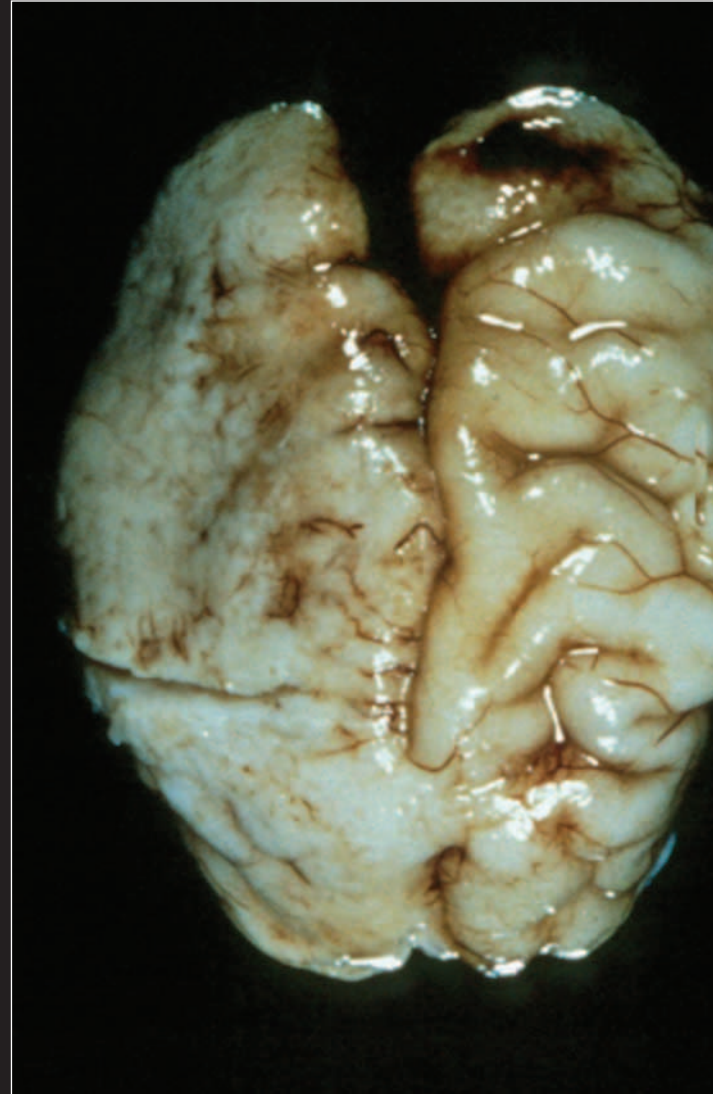


Red and yellow areas indicate the highest levels of activity.  
Blue and purple indicate the lowest levels of activity.

# Fetal Brain Damage Caused by Alcohol



Healthy Brain

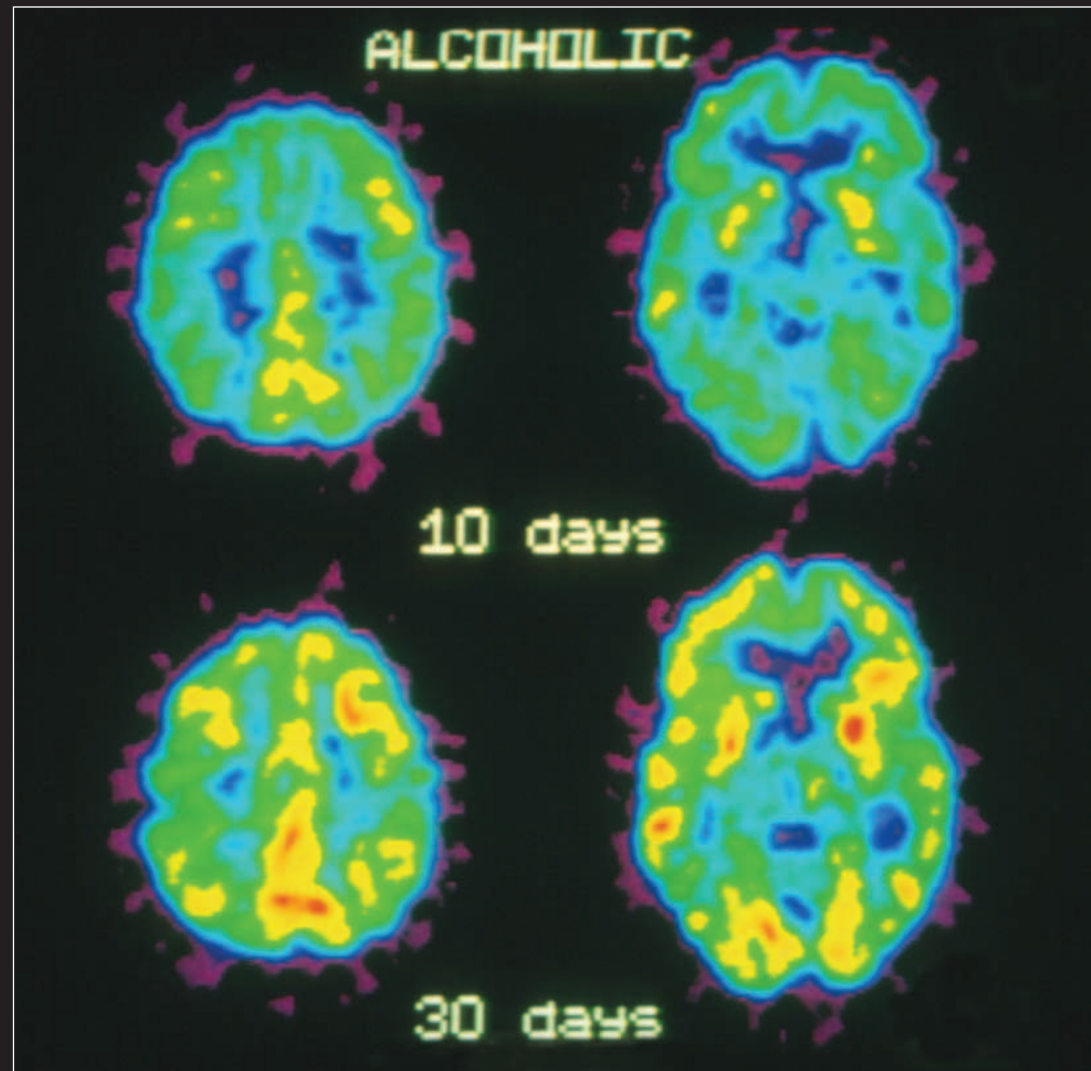


Fetal Alcohol Brain

Courtesy of Dr. Sterling Clarren



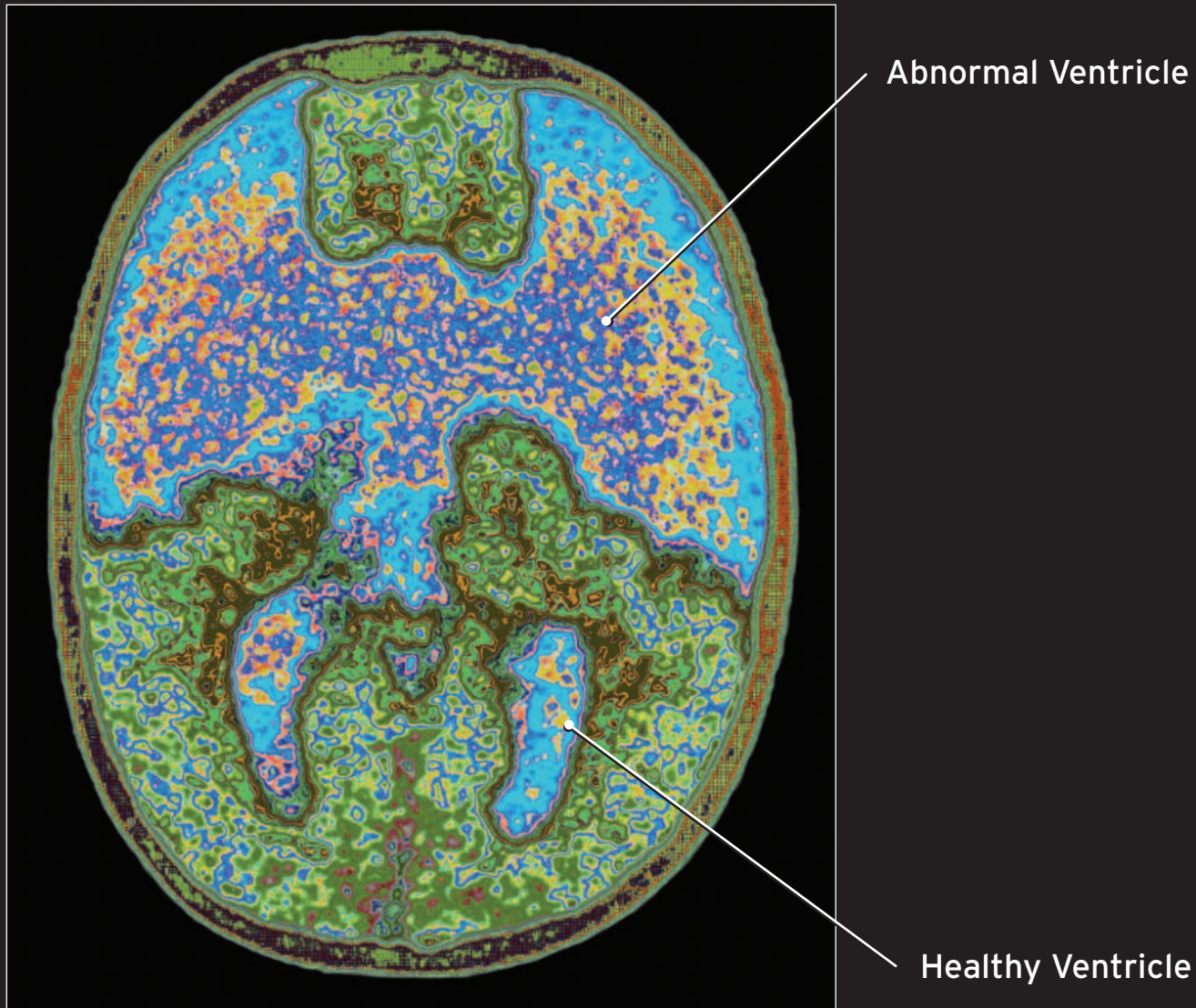
# PET Scans of the Effects of Alcohol Withdrawal



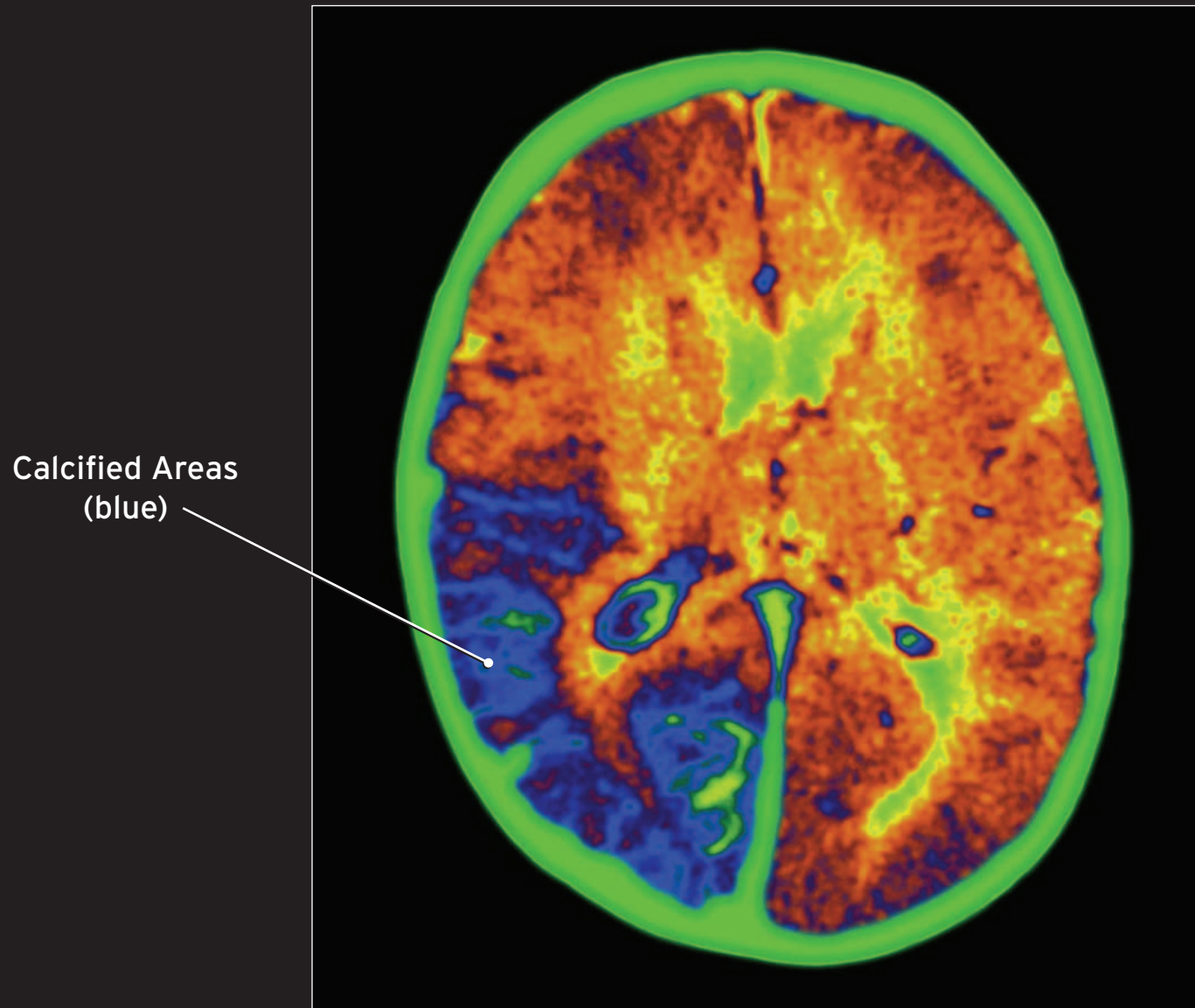
Red and yellow indicate the highest levels of activity.  
Blue and purple indicate the lowest levels of activity.



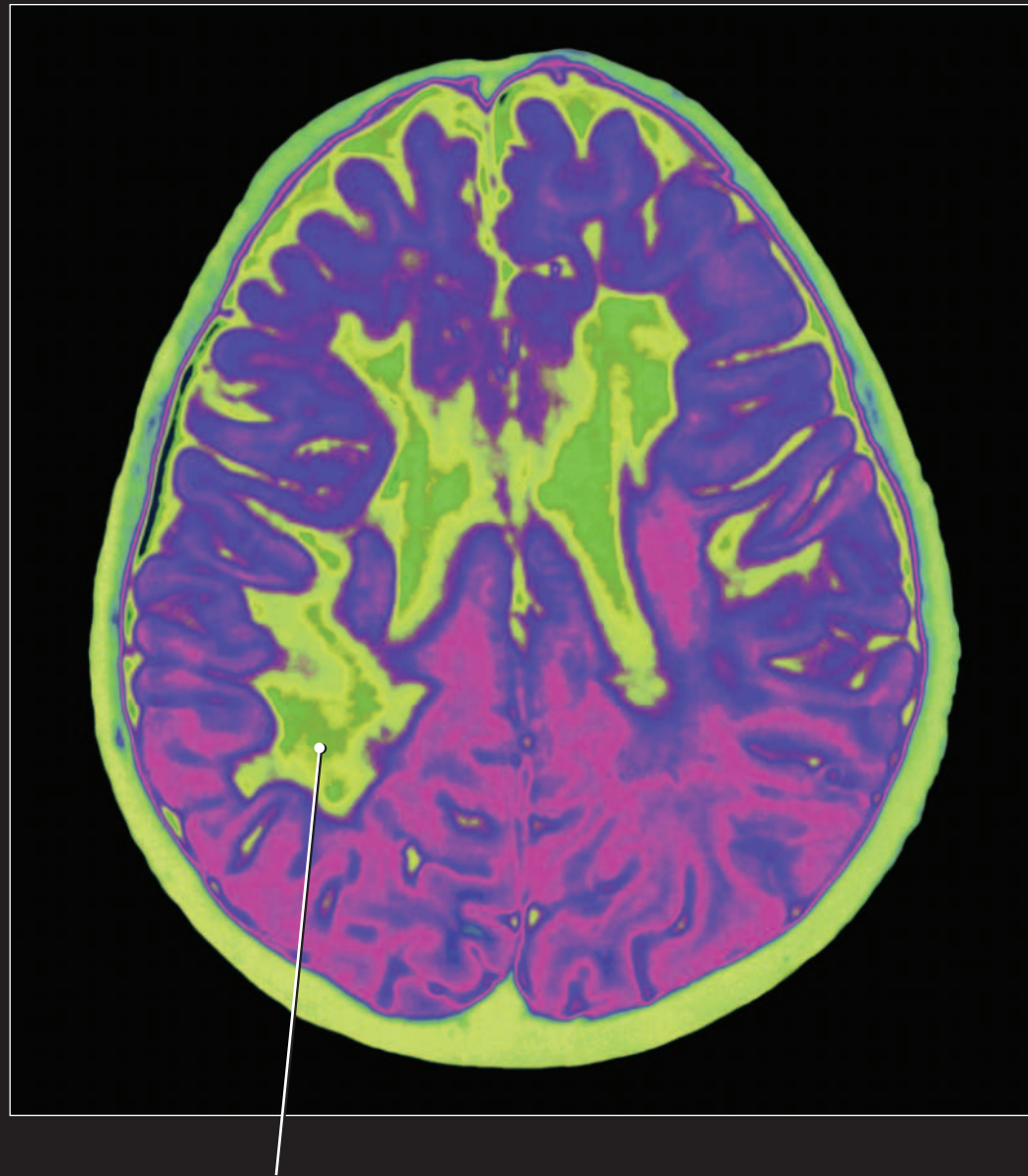
# MRI Scan of Brain with Holoprosencephaly



# MRI Scan of Brain with Sturge-Weber Syndrome



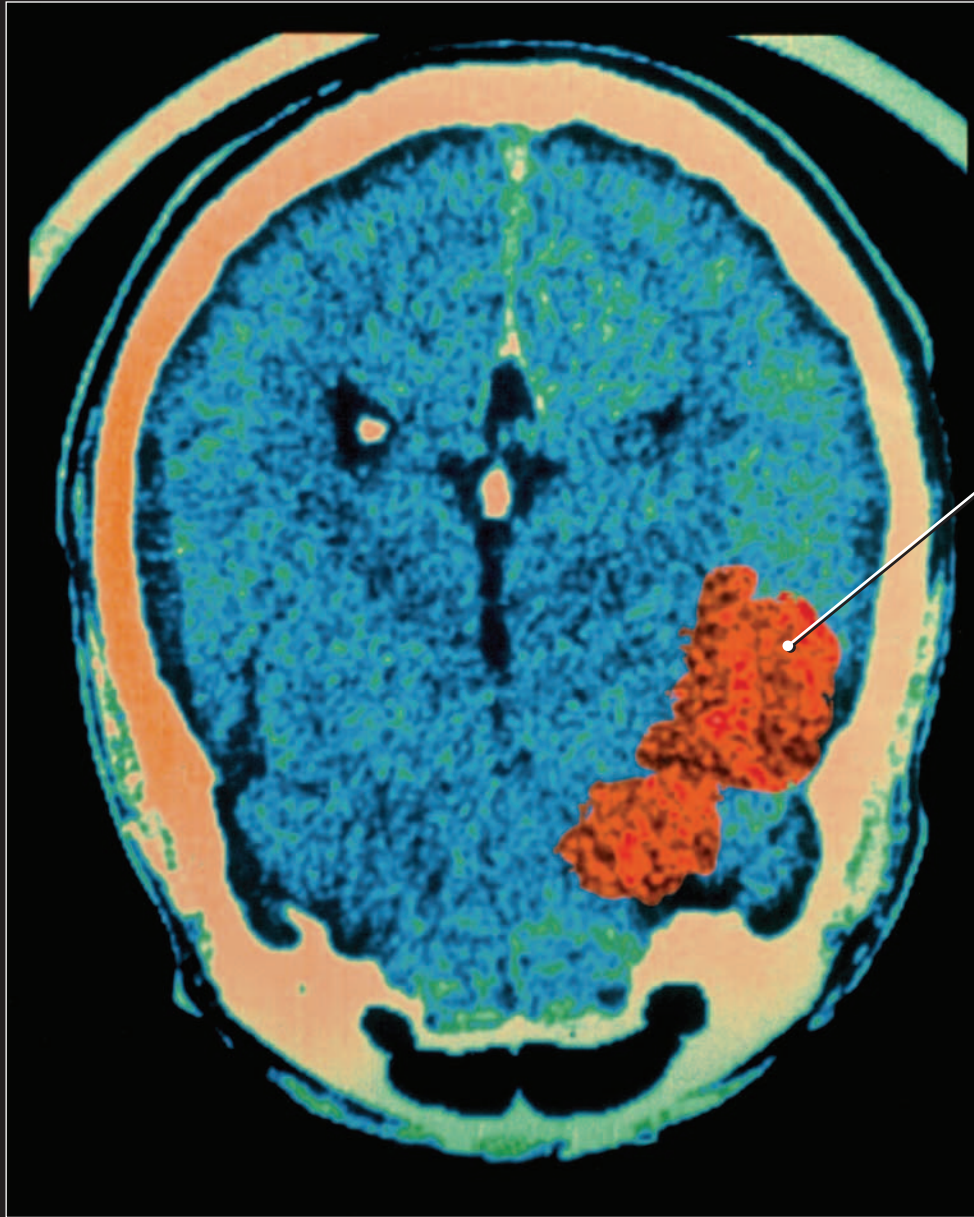
# MRI Scan of Brain with Multiple Sclerosis



Large Demyelinated Lesion

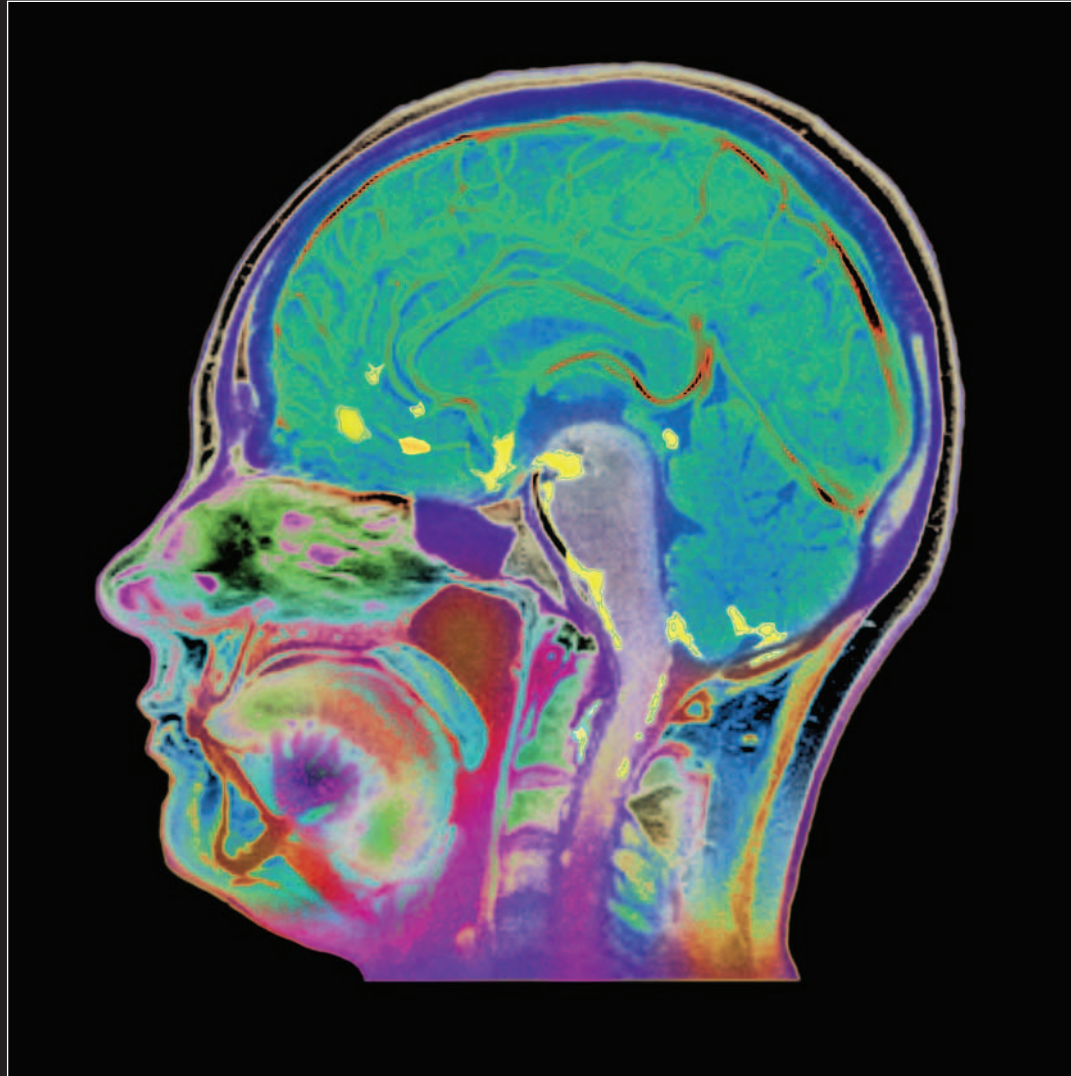


# CT Scan of Brain with Encephalitis



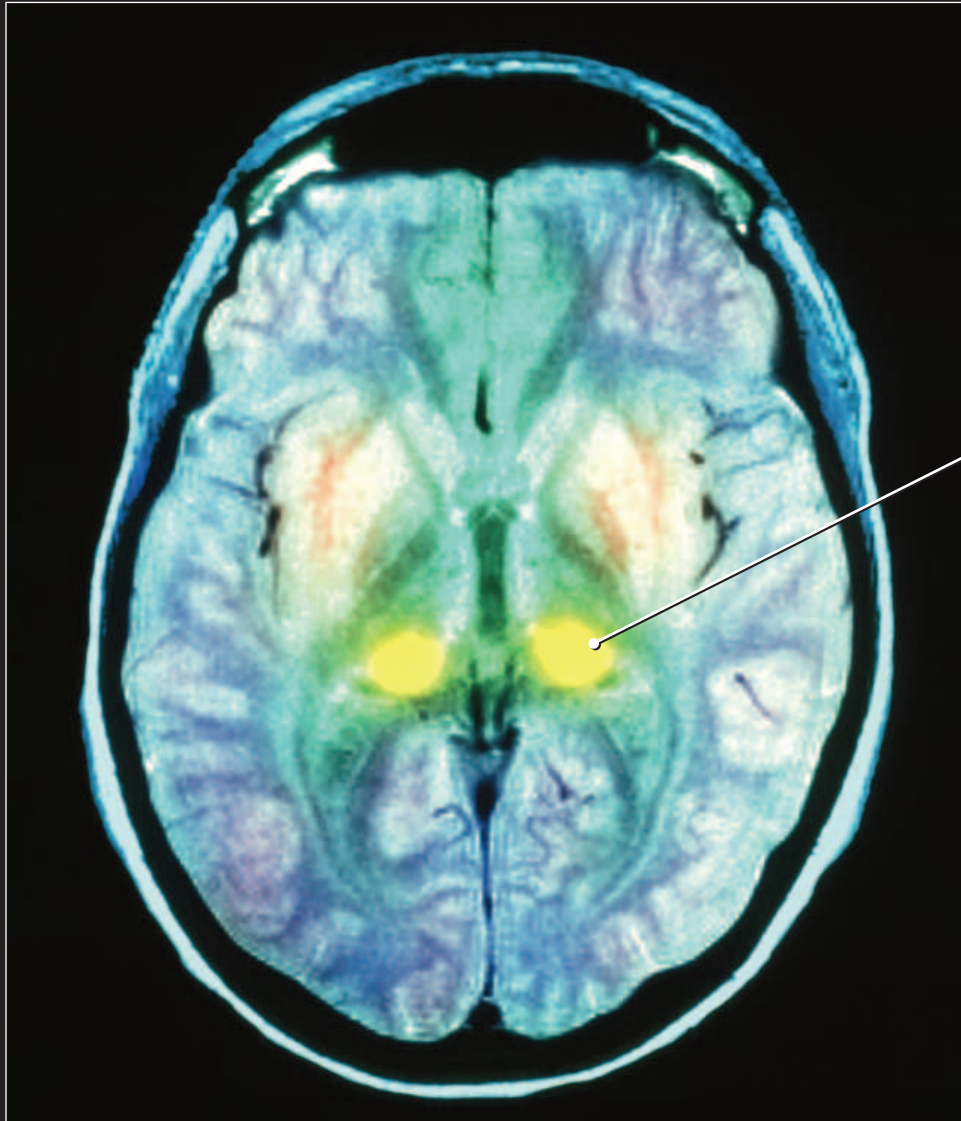
Inflammation of  
the Encephalon  
(red area)

# MRI Scan of Brain with Meningitis



Yellow areas on the brain and spinal cord indicate meningitis.

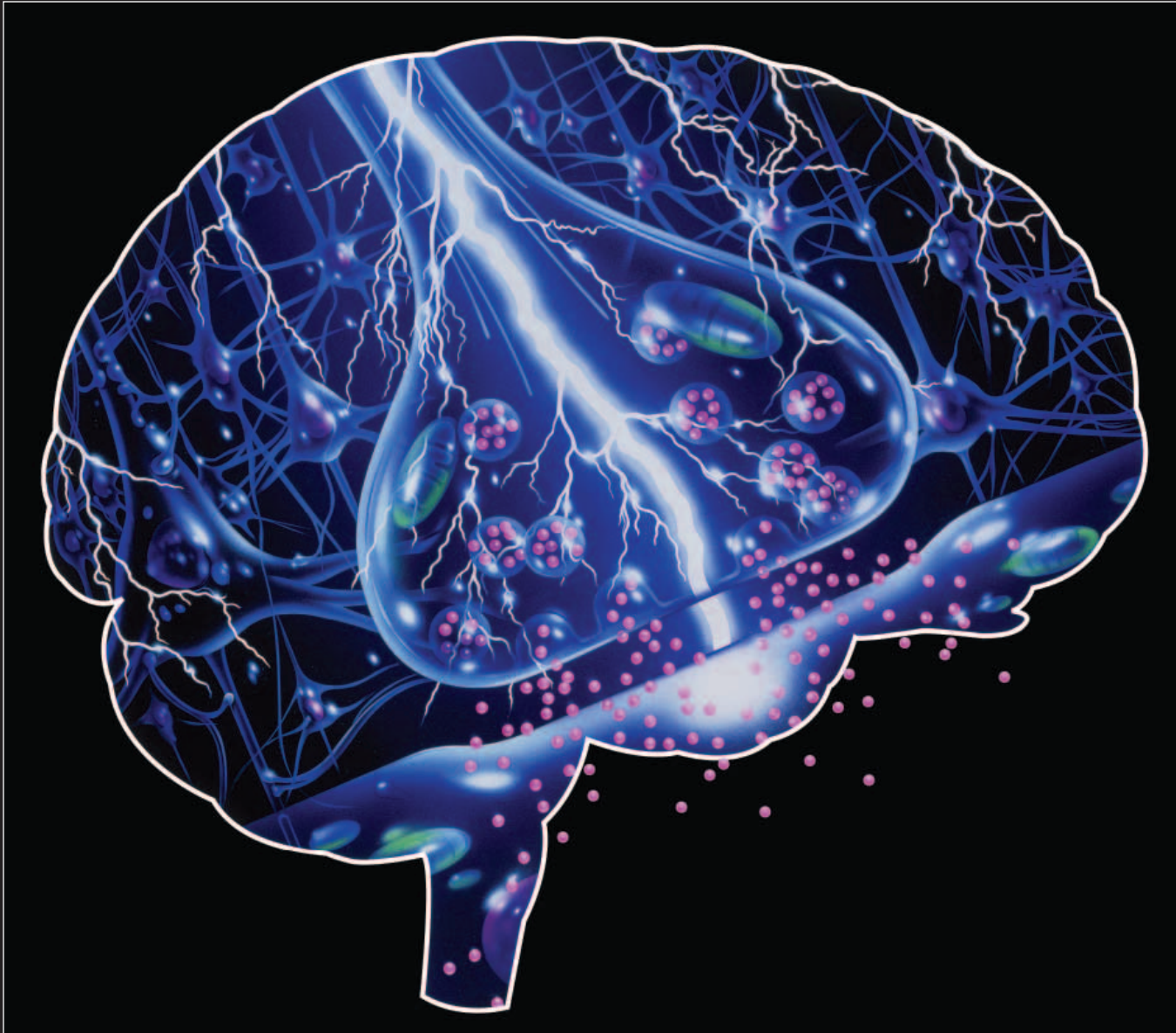
# MRI Scan of Brain with Creutzfeldt-Jakob Disease



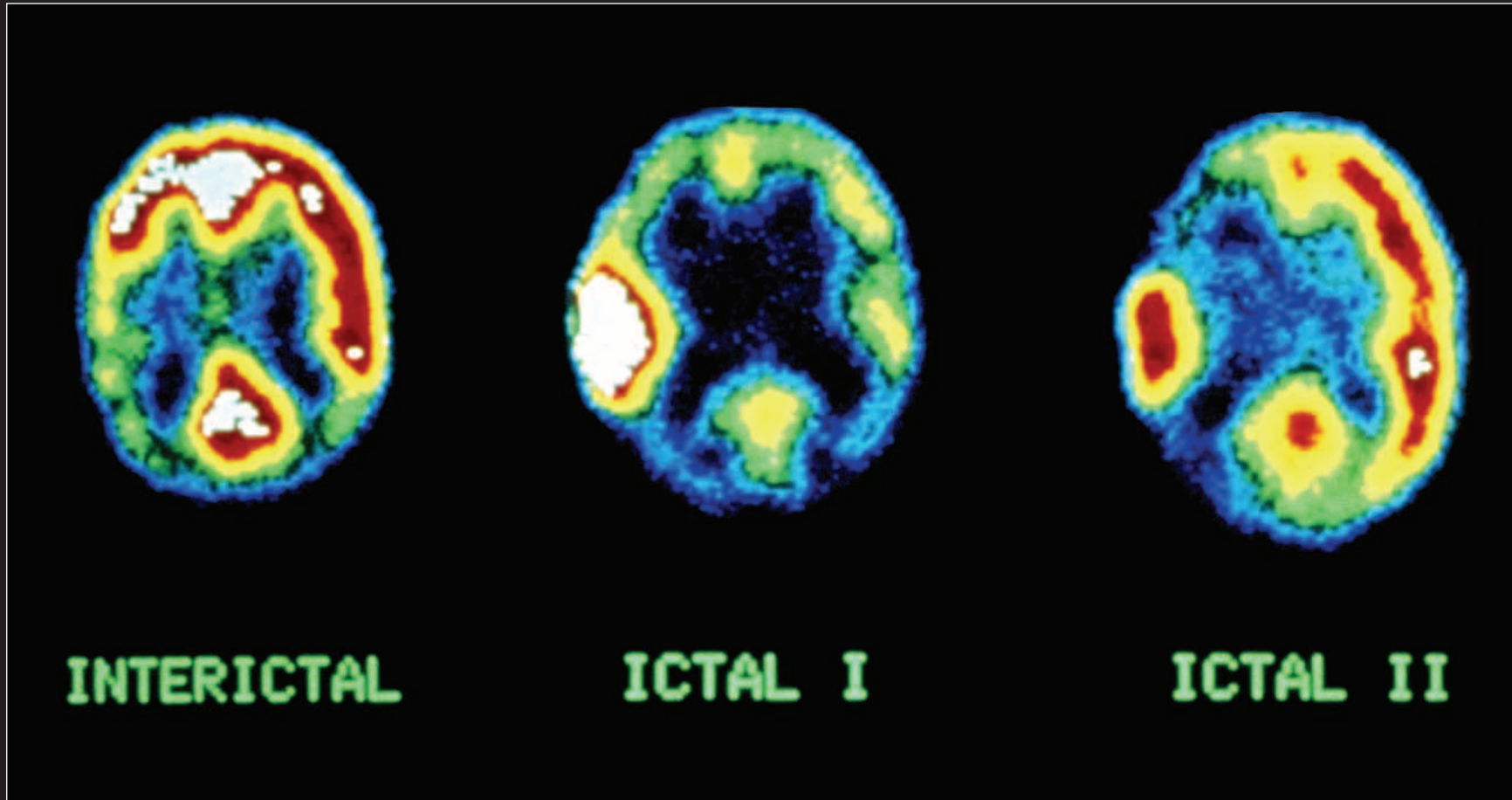
The two yellow areas of the thalamus show Creutzfeldt-Jakob disease (CJD).



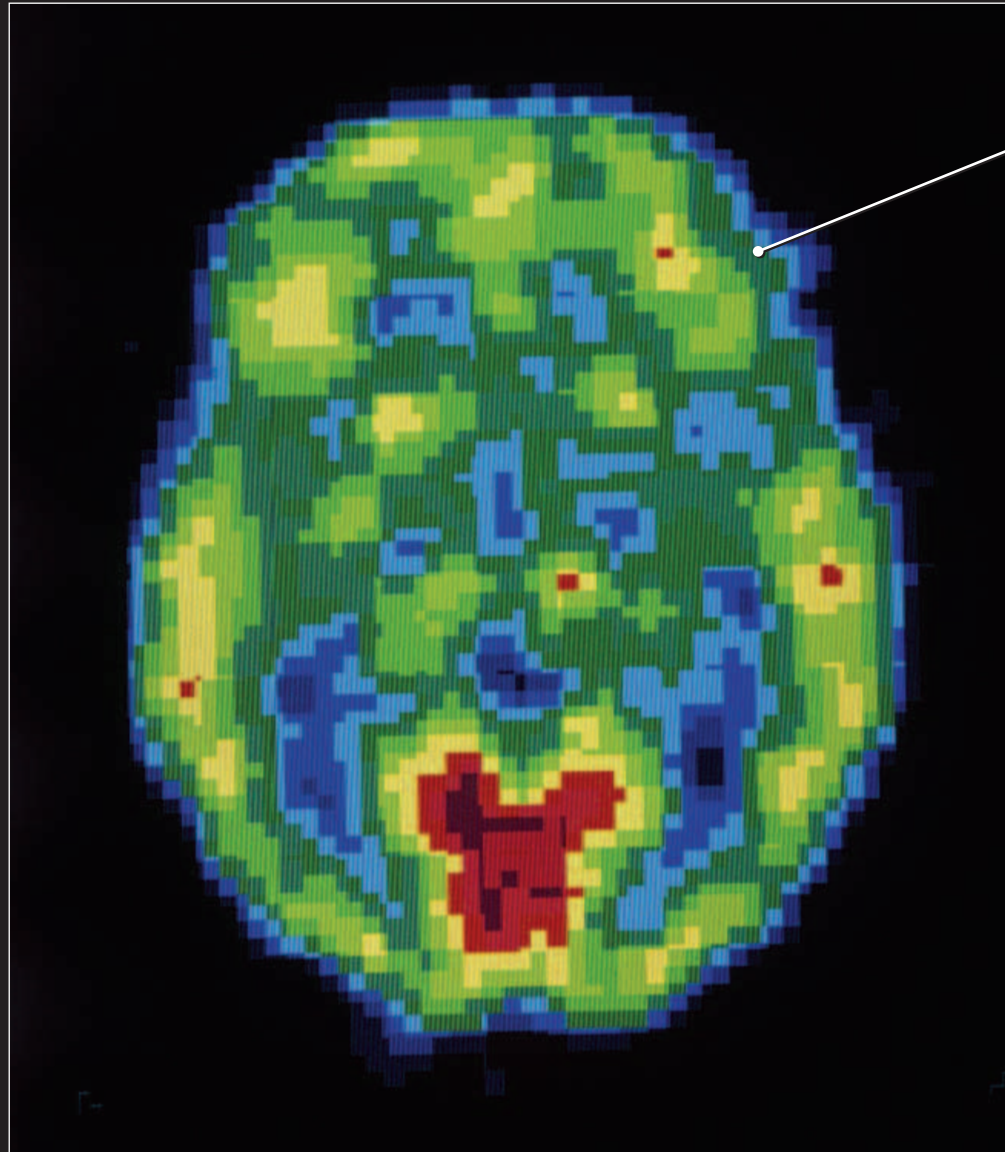
# Illustration of an Epileptic Seizure's Impact on the Brain



# PET Scans Showing the Stages of an Epileptic Seizure



# PET Scan of Brain with Schizophrenia (Off Medication)

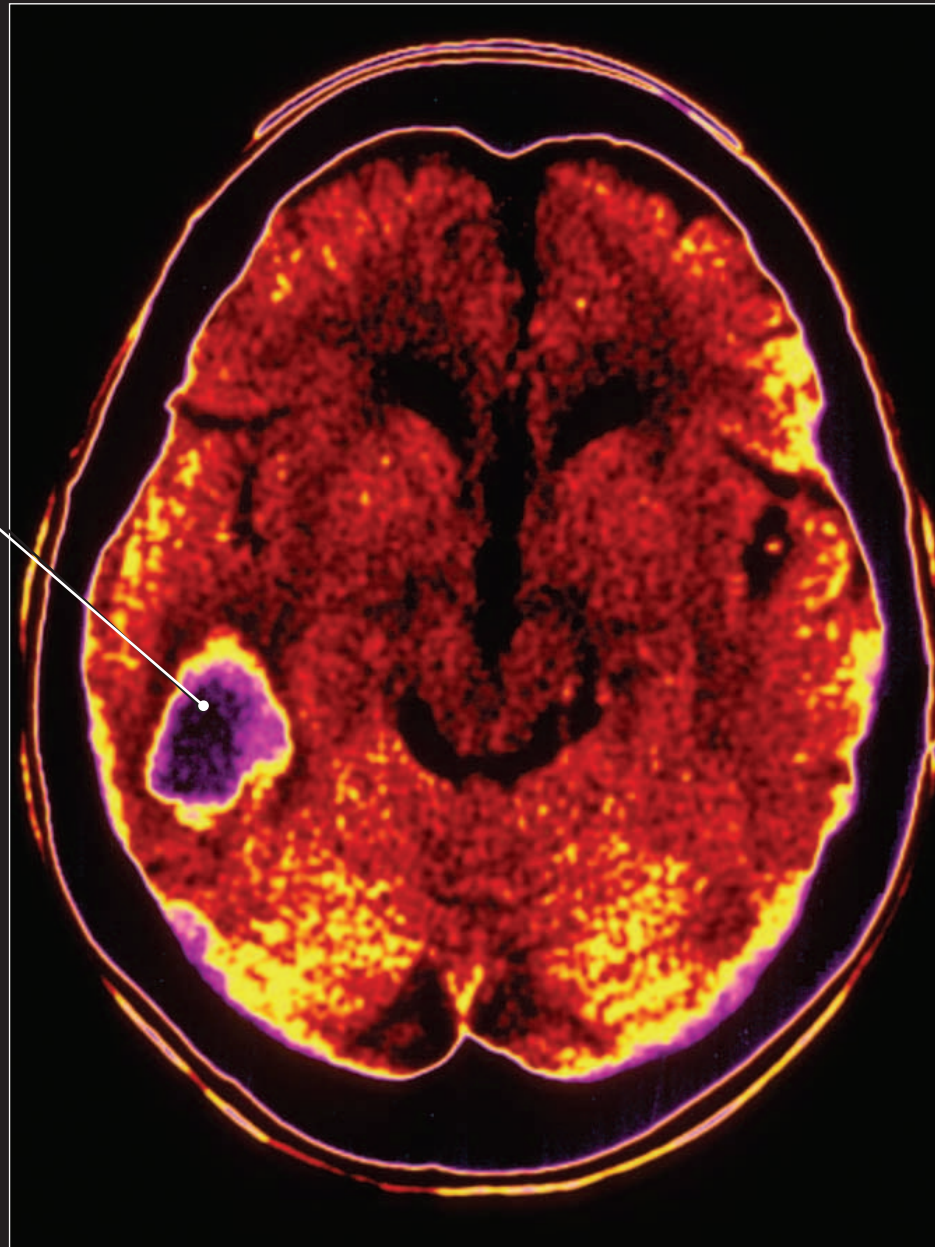


Low activity in the frontal lobe.

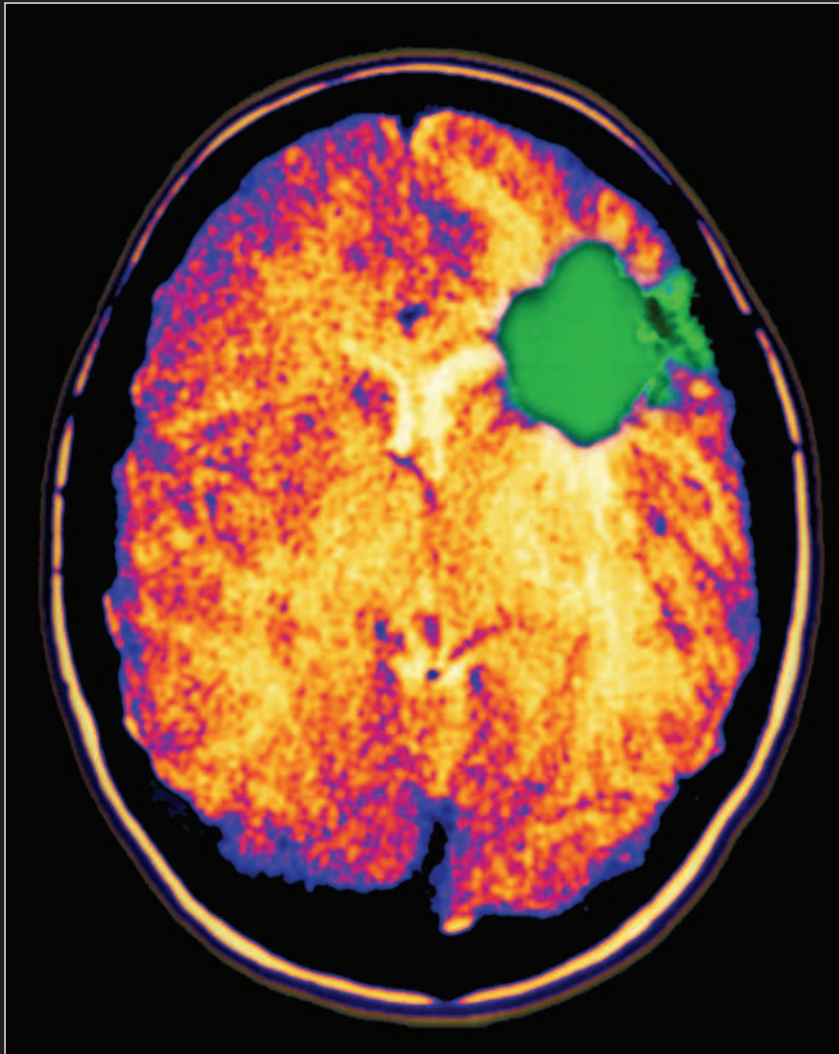


# CT Scan of Brain Hemorrhage

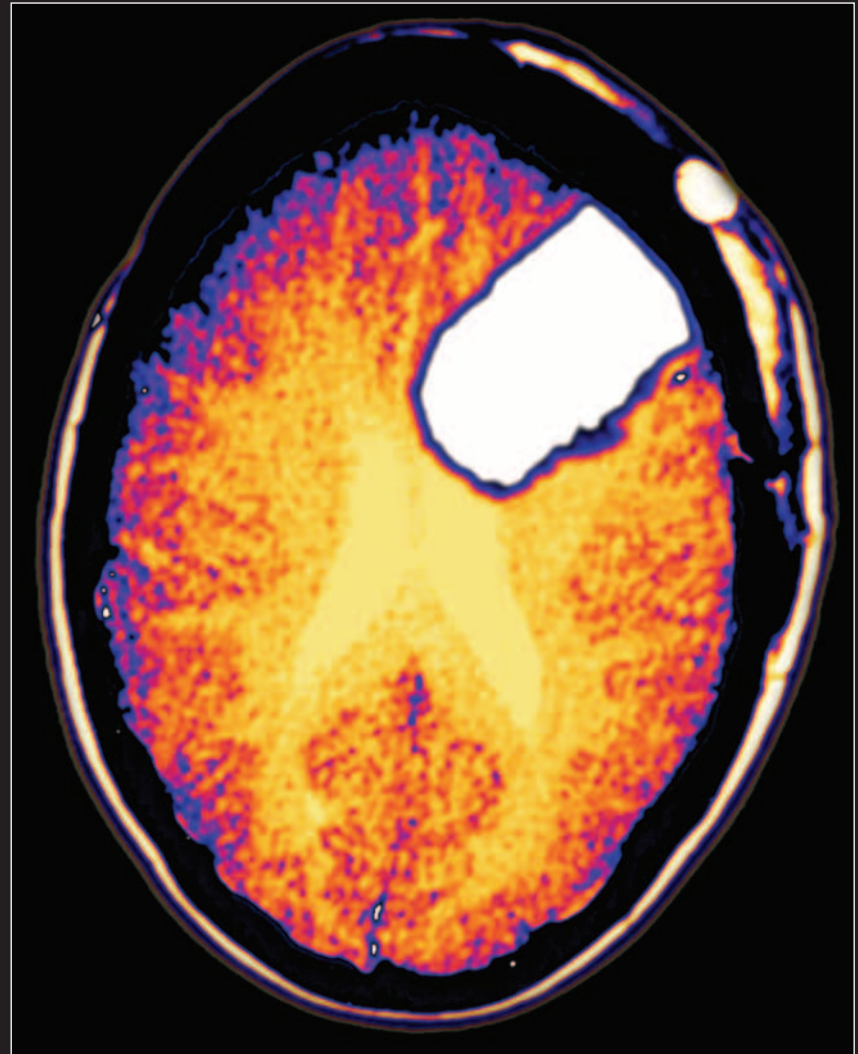
Hemorrhage occurred  
in the left posterior  
temporal lobe.



# CT Scan of Glioma (Tumor) and Removal

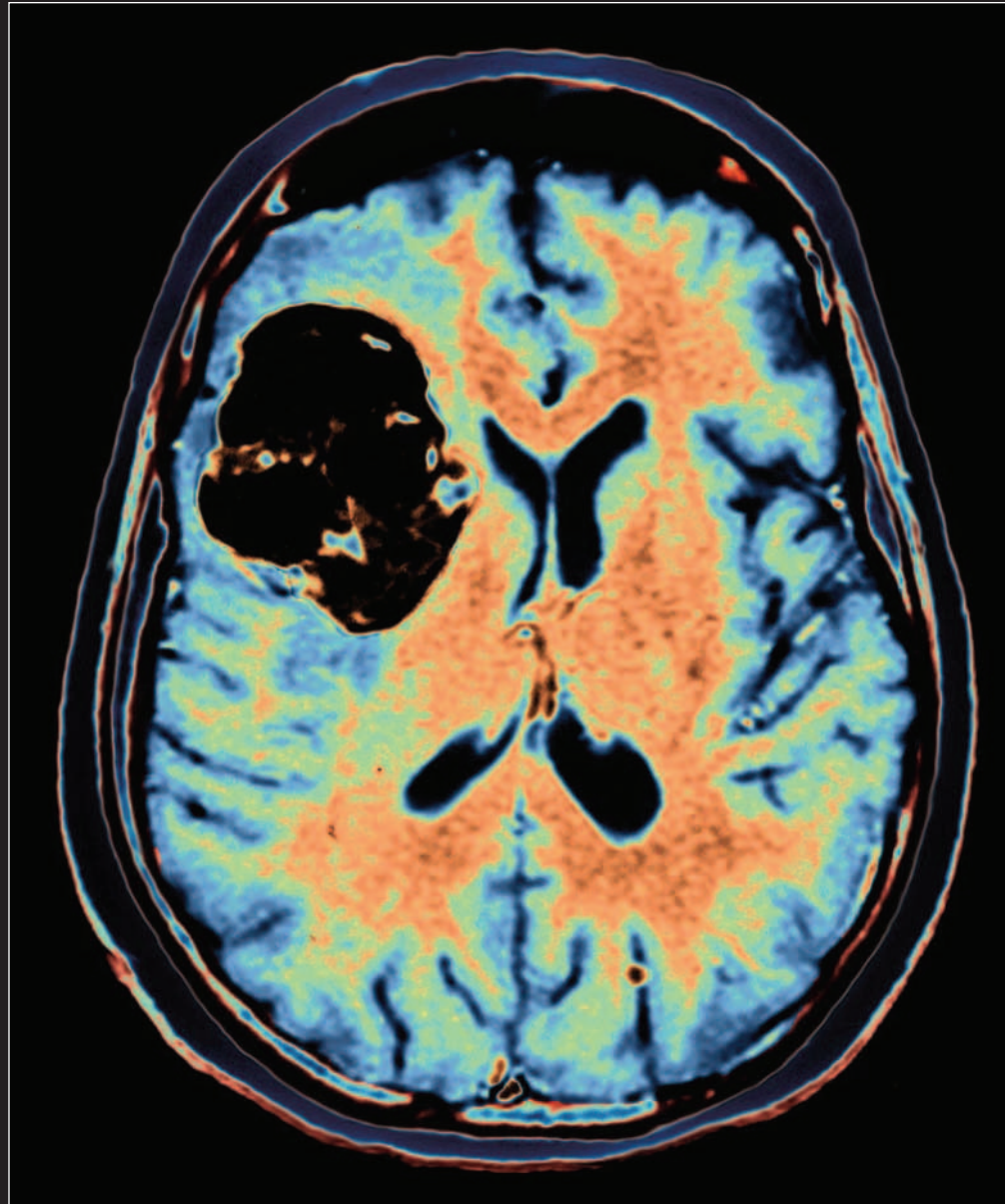


Glioma (tumor) is green.



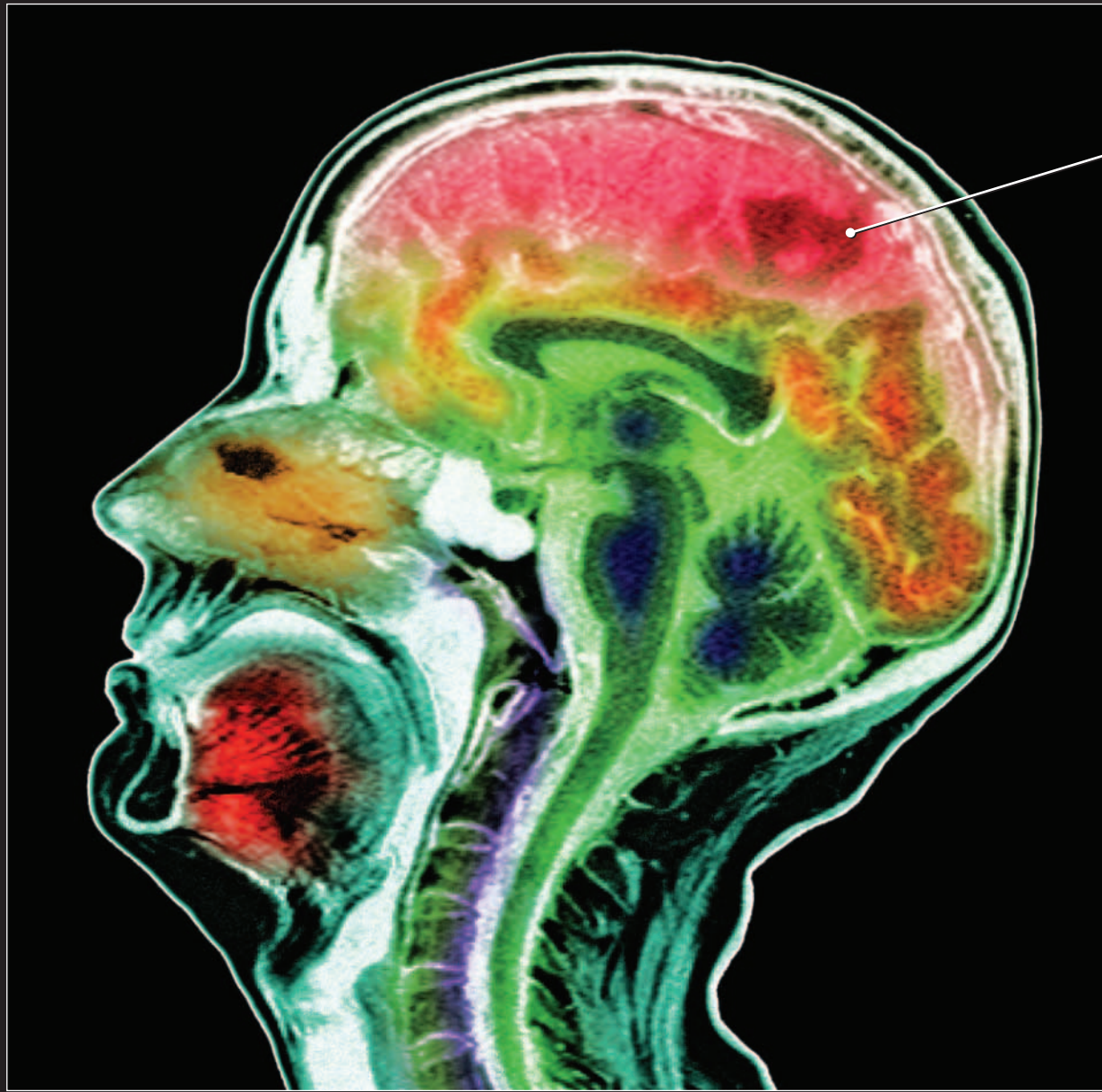
Glioma (tumor) has been removed.

# MRI Scan of Brain Cancer



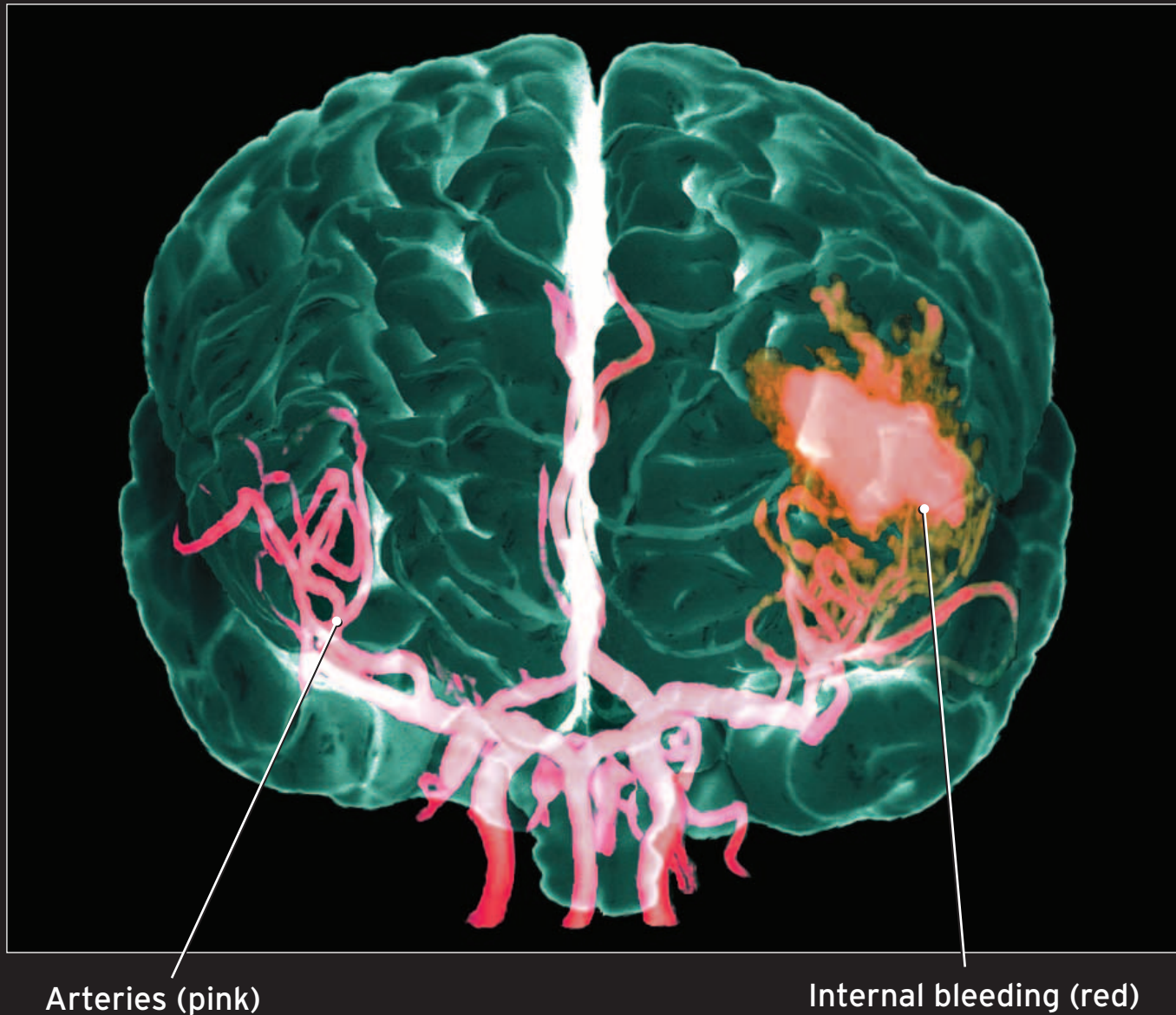

# MRI Scan of Cerebral Atrophy

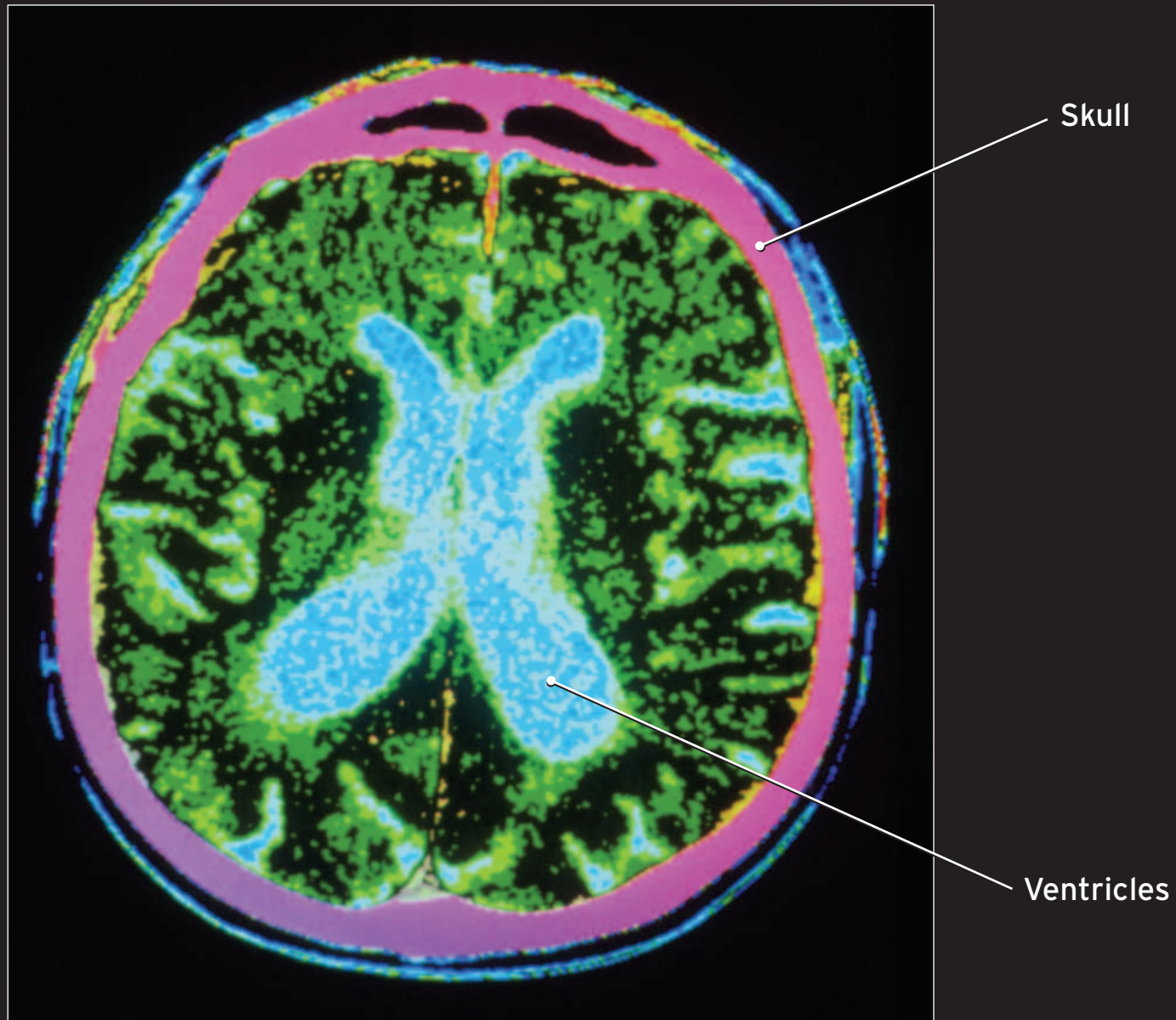


Dark red area  
shows atrophy of  
upper cerebrum.

# Magnetic Resonance Angiography (MRA) Showing a Stroke

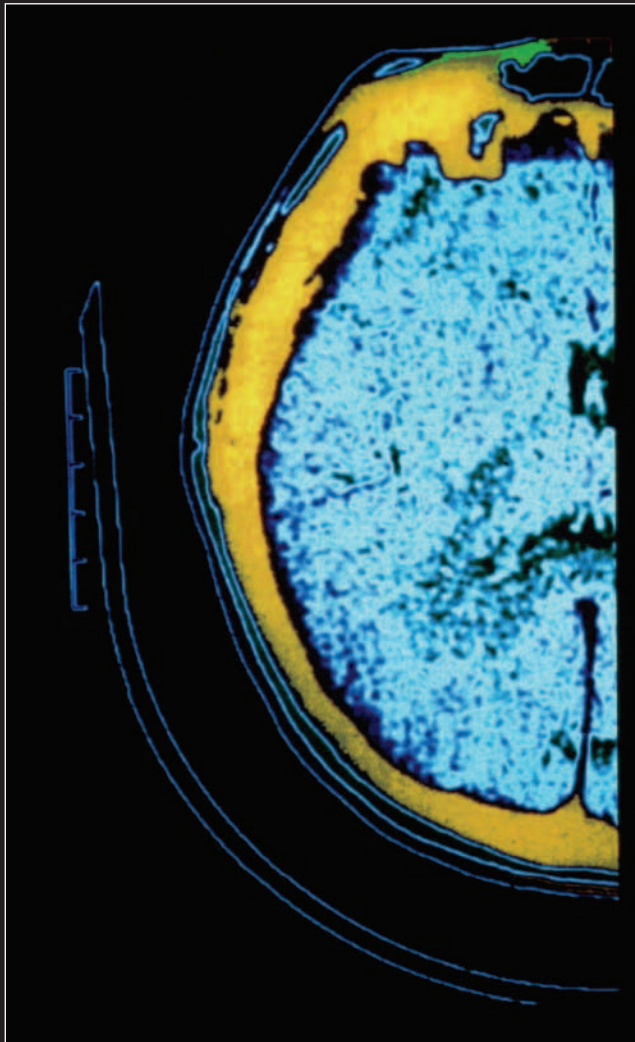


# CT Scan of Brain with Parkinson's Disease

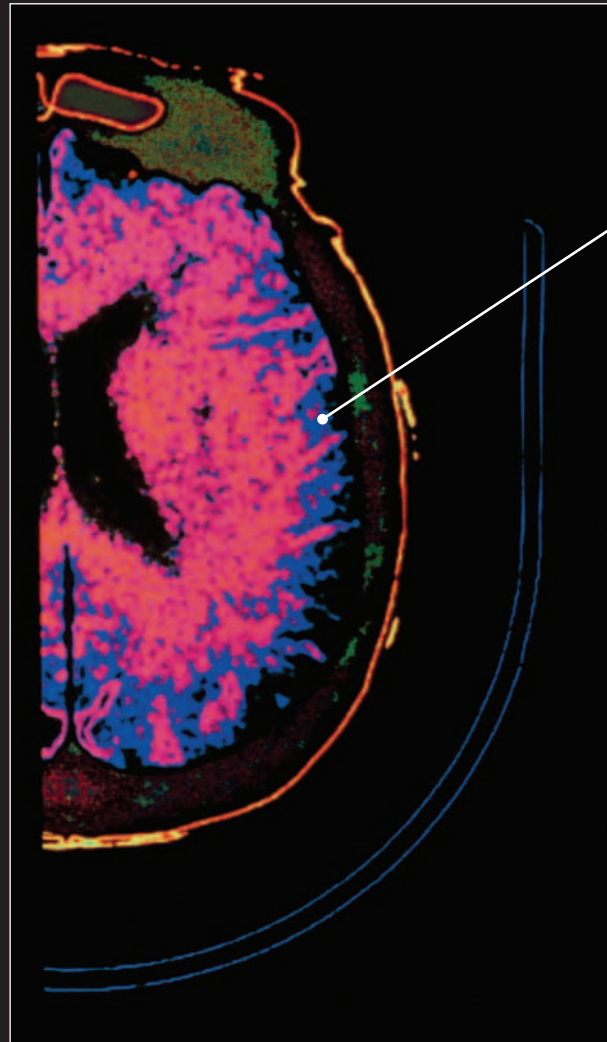




# CT Scans Showing the Effect of Alzheimer's on the Brain



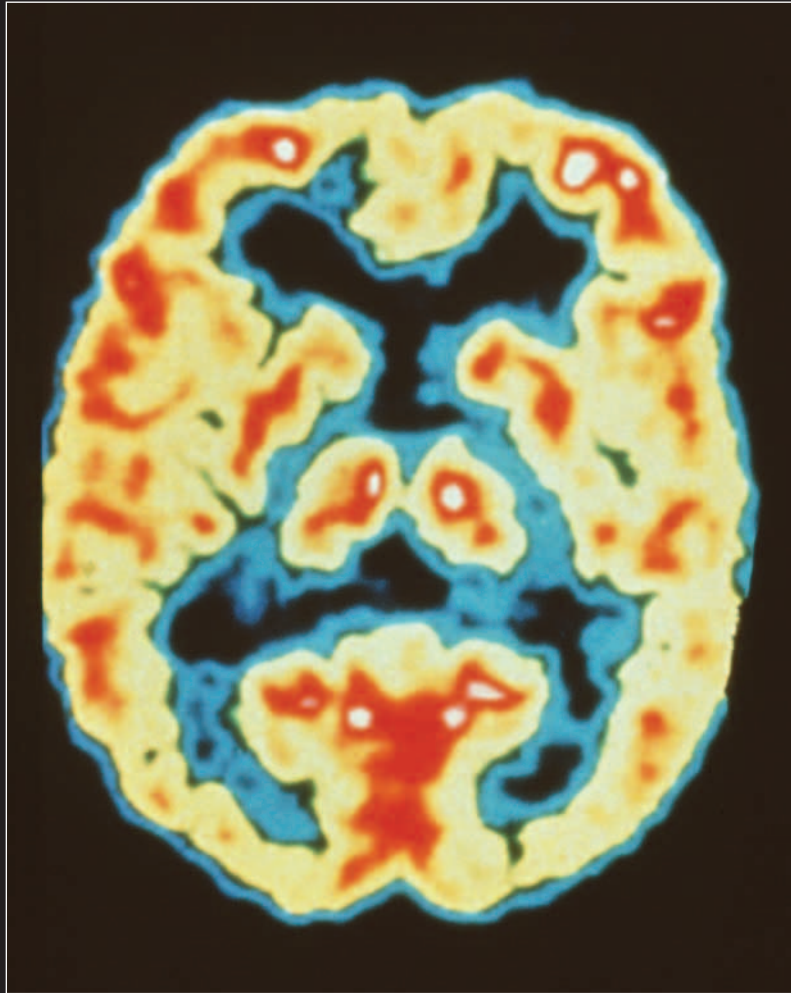
Healthy Brain



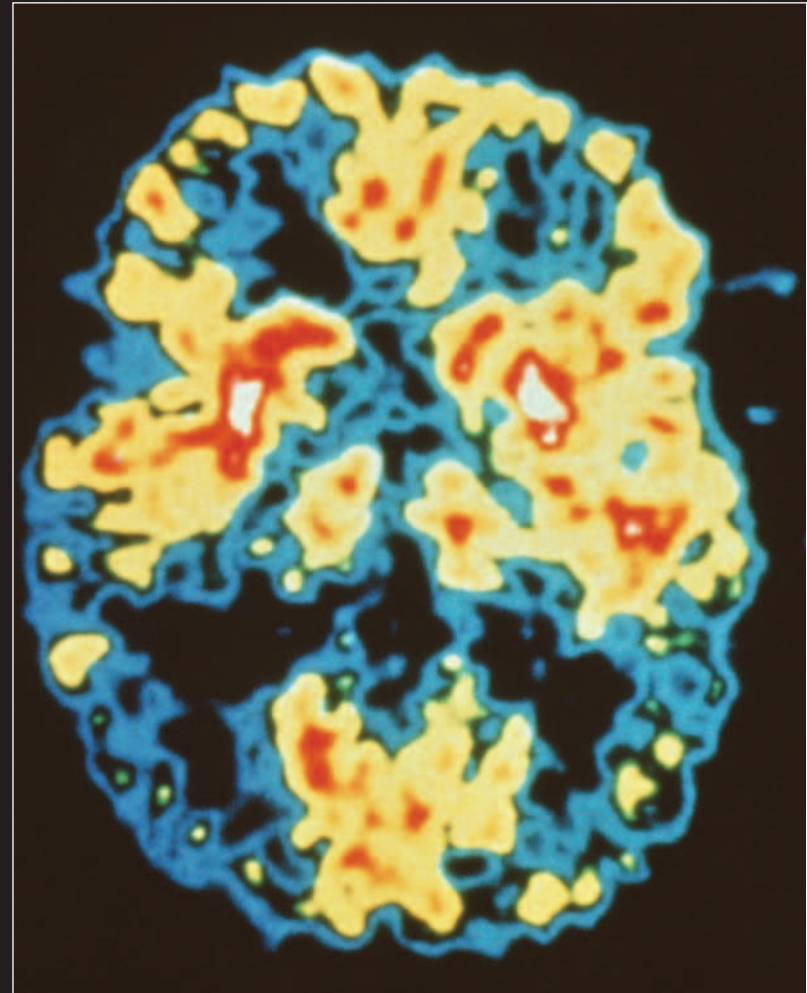
Alzheimer's Disease

Dark blue edges on the Alzheimer's scan indicate shrinkage of the brain (cortical atrophy).

# PET Scans Showing the Effect of Alzheimer's on the Brain



Healthy Brain



Alzheimer's Disease

Red and yellow indicate high brain activity.  
Blue and black indicate low brain activity.



# The Progression of Alzheimer's Disease

